

Thyroid nodular disease

Dr Nasser Aghamohammadzadeh

Professor Of Endocrinology

Tabriz University Of Medical Sciences

PHYSICAL EXAMINATION

- In addition to the ***examination of the thyroid itself***, the physical examination should include a search for ***signs of abnormal thyroid function*** and the extrathyroidal features of ***ophthalmopathy and dermopathy*** (Chap. 377).
- Examination of the neck begins by ***inspecting*** the seated patient from the front and side and noting any surgical scars, obvious masses, or distended veins. The thyroid can be ***palpated*** with both hands from behind or while facing the patient, using the thumbs to palpate each lobe.

- The patient's neck should be ***slightly flexed*** to relax the neck muscles. After locating the ***cricoid cartilage***, the ***isthmus***, which is attached to the lower one-third of the thyroid lobes, can be identified and then followed laterally to locate either lobe (normally, the right lobe is slightly larger than the left).
- By asking the patient to ***swallow*** sips of water, thyroid ***consistency*** can be better appreciated as the gland moves beneath the examiner's fingers.

- Features to be noted include thyroid :
- ***size,***
- ***consistency,***
- ***nodularity, and***
- ***any tenderness or***
- ***fixation.***
- An estimate of thyroid size (normally 12–20 g) should be made, and a drawing is often the best way to record findings.

- **Ultrasound imaging** provides the most accurate measurement of *thyroid volume and nodularity* and is useful for *assessment of goiter* prevalence in iodine deficient regions.
- However, ultrasound is not indicated if the thyroid physical examination is normal.
- The *size, location, and consistency of any nodules* should also be defined.
- A ***bruit or thrill*** over the gland, located over the insertion of the superior and inferior thyroid arteries (supero- or inferolaterally), indicates ***increased vascularity, associated with turbulent*** rather than laminar blood flow, as occurs in **hyperthyroidism**.

LABORATORY EVALUATION

- Measurement of Thyroid Hormones (***TSH, Free T4, Total T3***)
- Tests to Determine the ***Etiology of Thyroid Dysfunction (Anti TPO – Anti TG – TSI – TG)***
- ***Radioiodine Uptake*** and ***Thyroid Scanning*** (Graves – Toxic Adenoma – MNG – Thyroiditis – Nodules – Factitious)
- ***Thyroid Ultrasound*** (nodular thyroid disease) : hypo echoic solid nodules with infiltrative borders and micro calcifications, >90% cancer risk .

Thyroid Nodular Disease and Thyroid Cancer

- **Thyroid nodular disease** is characterized by the disordered growth of thyroid cells, which can be either **hyperplastic or neoplastic**.
- A patient may have a multinodular goiter (**MNG**) in which thyroid nodules (**generally hyperplastic**) replace the majority of the normal thyroid parenchyma; this presentation is more common in areas of borderline iodine deficiency.
- Or, the thyroid gland may be normal in size and contain discrete thyroid nodules.

- **Nodular thyroid disease** is common, occurring in about **3–7%** of adults when assessed by physical examination.
- Using ultrasound, nodules are present in up to **50%** of adults, with the majority being **<1 cm** in diameter.
- Thyroid nodules may be **solitary or multiple**, and they may be **functional or nonfunctional**.

NONTOXIC MULTINODULAR GOITER :

- **Etiology and Pathogenesis :**
- up to 12% of adults
- more common in women than men and increases with age
- more common in iodine-deficient region
- multiple genetic, autoimmune, and environmental influences on the pathogenesis.
- hypercellular, hyperplastic regions to cystic areas filled with colloid

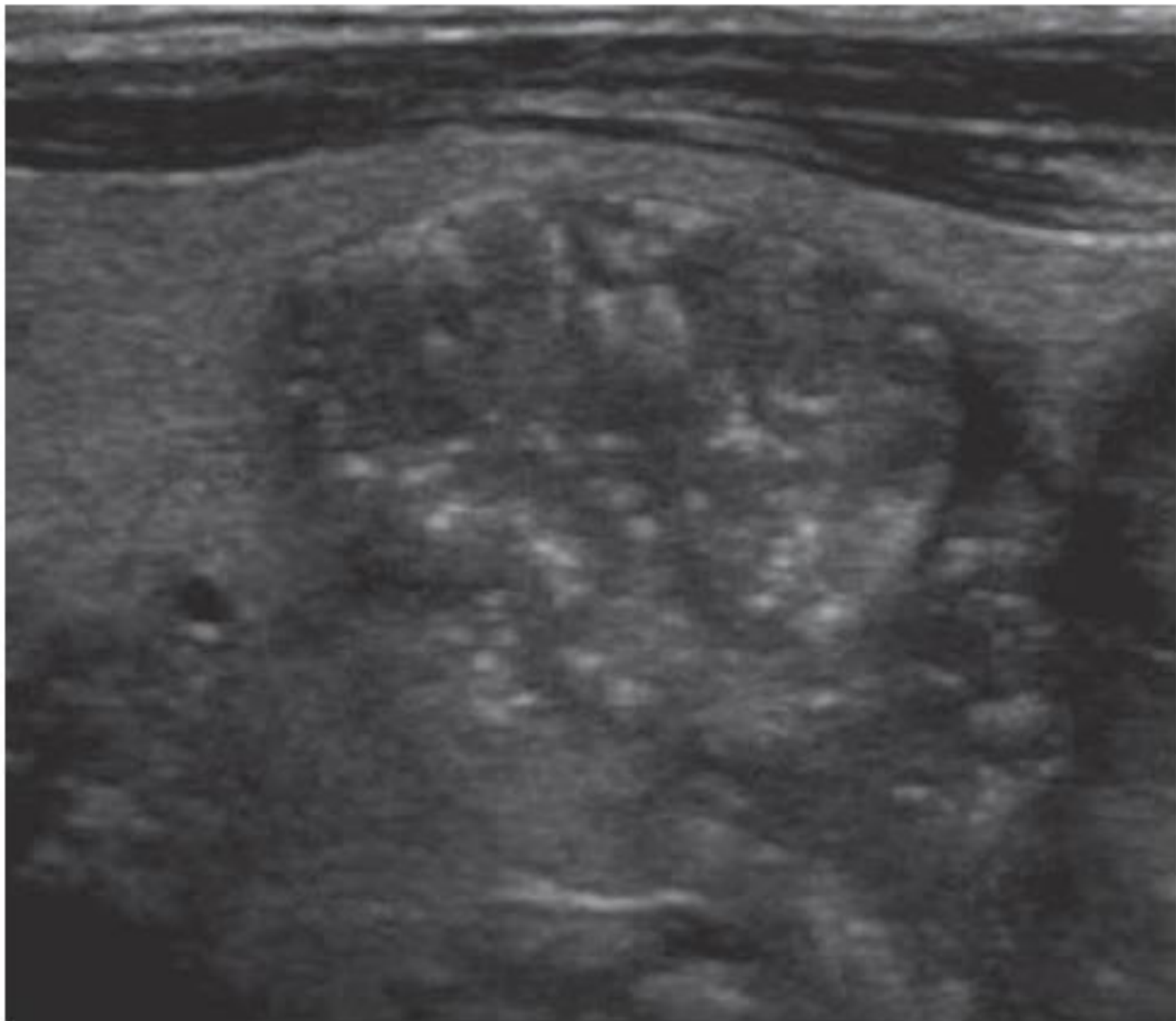
- **Fibrosis** is often extensive, and areas of **hemorrhage** or **lymphocytic infiltration** may be seen.
- Using molecular techniques, most nodules within an MNG are **polyclonal** in origin, suggesting a hyperplastic response to locally produced **growth factors and cytokines**.
- **Monoclonal** neoplastic lesions may also occur, reflecting mutations in genes that confer a selective growth advantage to the progenitor cell.

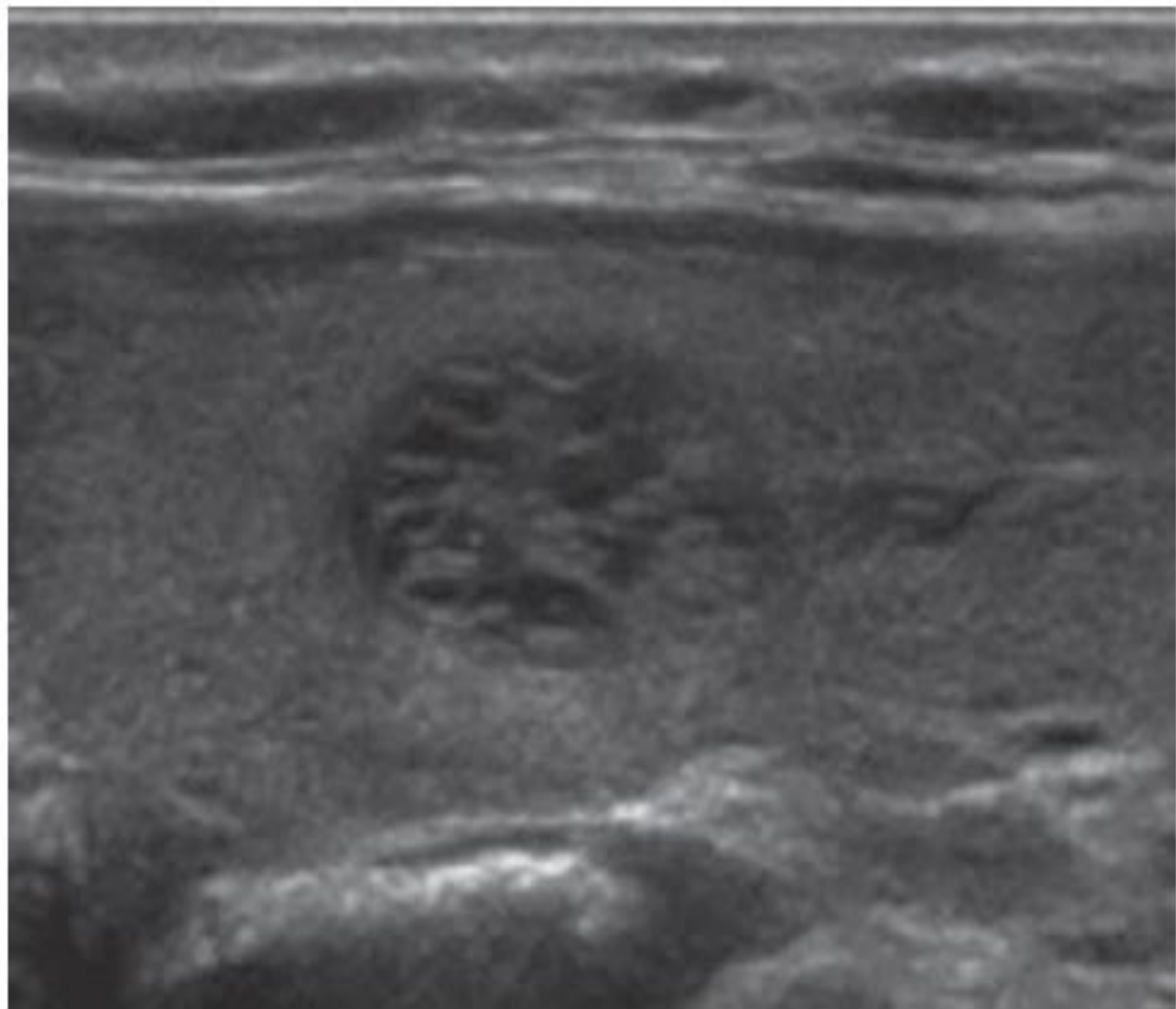
Diagnosis :

- Examination
- Pemberton's sign
- TSH level
- Tracheal deviation and compression
- Pulmonary function testing
- CT or MRI
- A barium swallow
- Ultrasonography can be used to identify which nodules should be biopsied based on a combination of size and sonographic features

TABLE 378-1 Grayscale Sonographic Features Associated with Thyroid Cancer

	MEDIAN SENSITIVITY [RANGE]	MEDIAN SPECIFICITY [RANGE]
Hypoechoic compared with surrounding thyroid	81% [48–90%]	53% [36–92%]
Marked hypoechogenicity	41% [27–59%]	94% [92–94%]
Microcalcifications	44% [26–73%]	89% [69–98%]
Irregular, microlobulated margins	55% [17–84%]	79% [62–85%]
Solid consistency	86% [78–91%]	48% [30–58%]
Taller than wide shape on transverse view	48% [33–84%]	92% [82–93%]





BENIGN LESIONS :

- Benign nodules may be **hyperplastic** and reflect a combination of both macro- and microfollicular architecture or they may be **neoplastic**, encapsulated adenomas that generally have a more monotonous microfollicular pattern.
- If the adenoma is composed of oncocytic follicular cells arranged in a follicular pattern, this is termed a **Hürthle cell** adenoma.
- Hyperplastic nodules generally appear as **mixed cystic/ solid** or **spongiform** lesions on ultrasound.

- However, the **majority** of solid nodules (whether hypo-, iso-, or hyperechoic) are also **benign**.
- **FNA**, usually performed with ultrasound guidance, is the diagnostic procedure of choice to evaluate thyroid nodules.
- Pure thyroid cysts, <1% of all thyroid growths, consist of colloid and are benign as well.

TABLE 378-2 Classification of Thyroid Growths

Benign	
Hyperplasia Colloid nodule	
Follicular epithelial cell adenomas Conventional Oncocytic (Hürthle cell)	
Malignant	Approximate Prevalence, %
Follicular epithelial cell	
Papillary carcinomas	80–85
Classic variant	
Follicular variant	
Diffuse sclerosing variant	
Tall cell, columnar cell variants	
Follicular carcinomas	2–5–7
Conventional	
Oncocytic (Hürthle cell)	
Poorly differentiated carcinomas	3–5
Anaplastic (undifferentiated) carcinomas	1
C cell origin (calcitonin-producing)	
Medullary thyroid cancer	<10
Sporadic	
Familial	
MEN 2	
Other malignancies	
Lymphomas	1
Metastases	
Breast, melanoma, lung, kidney	
Others	

Abbreviation: MEN, multiple endocrine neoplasia.

THYROID CANCER

TABLE 378-3 Risk Factors for Thyroid Carcinoma in Patients with Thyroid Nodule from History and Physical Examination

History of head and neck irradiation before the age of 18, including, mantle radiation for Hodgkin's disease, and brain radiation for childhood leukemia or other cranial malignancies

Exposure to ionizing radiation from fallout in childhood or adolescence

Age <20 or >65 years

Rapidly enlarging neck mass

Male gender

Family history of papillary thyroid cancer in 2 or more first degree relatives, MEN 2, or other genetic syndromes associated with thyroid malignancy (e.g., Cowden's syndrome, familial polyposis, Carney complex, PTEN [phosphatase and tensin homolog] hamartoma tumor)

Vocal cord paralysis, hoarse voice

Nodule fixed to adjacent structures

Lateral cervical lymphadenopathy

Abbreviation: MEN, multiple endocrine neoplasia.

TABLE 378-4 Thyroid Cancer Classification^a

Papillary or Follicular Thyroid Cancers		
	<45 years	>45 years
Stage I	Any T, any N, M0	T1, N0, M0
Stage II	Any T, any N, M1	T2, N0, M0
Stage III	—	T3, N0, M0 T1–T3, N1a, M0
Stage IVA	—	T4a, any N, M0 T1–T3, N1b, M0
Stage IVB		T4b, any N, M0
Stage IVC		Any T, any N, M1
Anaplastic Thyroid Cancer		
Stage IV	All cases are stage IV	
Medullary Thyroid Cancer		
Stage I	T1, N0, M0	
Stage II	T2 or T3, N0, M0	
Stage III	T1–T3, N1a, M0	
Stage IVA	T4a, any N, M0 T1–T3, N1b, M0	
Stage IVB	T4b, any N, M0	
Stage IVC	Any T, any N, M1	

^aCriteria include: T, the size and extent of the primary tumor (T1a ≤1 cm; T1b >1 cm but ≤2 cm; T2 >2 cm but ≤4 cm; T3 >4 cm or any tumor with extension into perithyroidal soft tissue or sternothyroid muscle; T4a invasion into subcutaneous soft tissues, larynx, trachea, esophagus, or recurrent laryngeal nerve; T4b invasion into prevertebral fascia or encasement of carotid artery or mediastinal vessels); N, the absence (N0) or presence (N1a level IV central compartment; N1b levels II–V lateral compartment, upper mediastinal or retro/parapharyngeal) of regional node involvement; M, the absence (M0) or presence (M1) of distant metastases.

Note that updated TNM classification was released in early 2018.

Source: American Joint Committee on Cancer staging system for thyroid cancers using the TNM classification, 7th edition.

APPROACH TO THE PATIENT

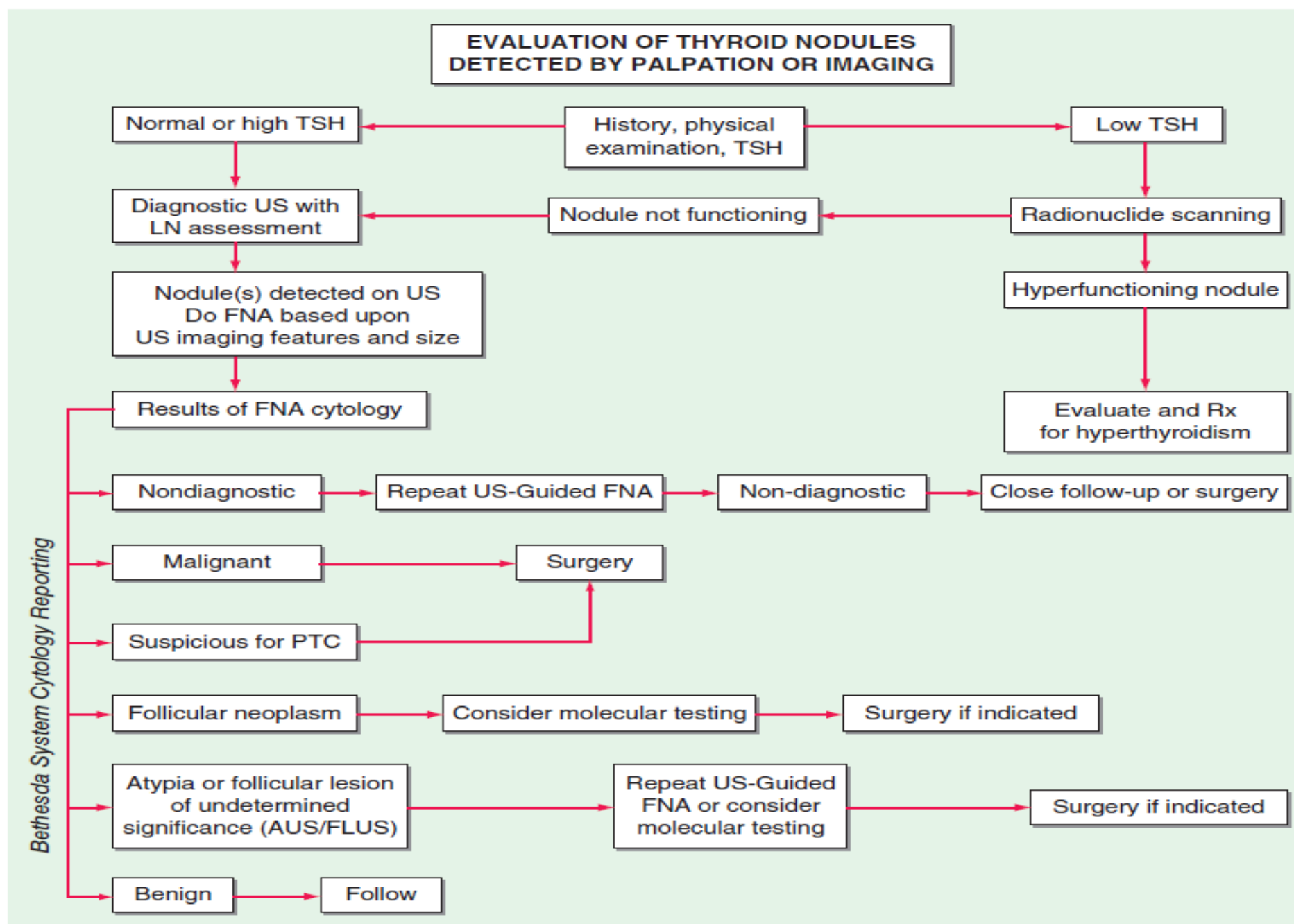


FIGURE 378-4 Approach to the patient with a thyroid nodule. See text and references for details. FNA, fine-needle aspiration; LN, lymph node; PTC, papillary thyroid cancer; TSH, thyroid-stimulating hormone; US, ultrasound.

TABLE 378-5 Bethesda Classification for Thyroid Cytology

DIAGNOSTIC CATEGORY	RISK OF MALIGNANCY
I. Nondiagnostic or unsatisfactory	1–5%
II. Benign	2–4%
III. Atypia or follicular lesion of unknown significance (AUS/FLUS)	5–15%
IV. Follicular neoplasm	15–30%
V. Suspicious for malignancy	60–75%
VI. Malignant	97–100%

COMPOSITION
(choose 1)

Cystic	0
Spongiform	0
Mixed cystic / solid	1
Solid	2

ECHOGENICITY
(choose 1)

Anechoic	0
Hyper- or Isoechoic	1
Hypoechoic	2
Very Hypoechoic	3

SHAPE
(choose 1)

Wider-than-tall	0
Taller-than-wide	3

MARGIN
(choose 1)

Smooth	0
Ill-defined	0
Lobulated or irregular	2
Extra-thyroidal extention.....	3

ECHOGENIC FOCI
(choose all that apply)

None or large comet-tail artifacts	0
Macrocalcifications	1
Peripheral (rim) calcifications	2
Punctate echogenic foci	3

Add points for TI-RADS level

0 points

TR1
Benign
No FNA

2 points

TR2
Not suspicious
No FNA

3 points

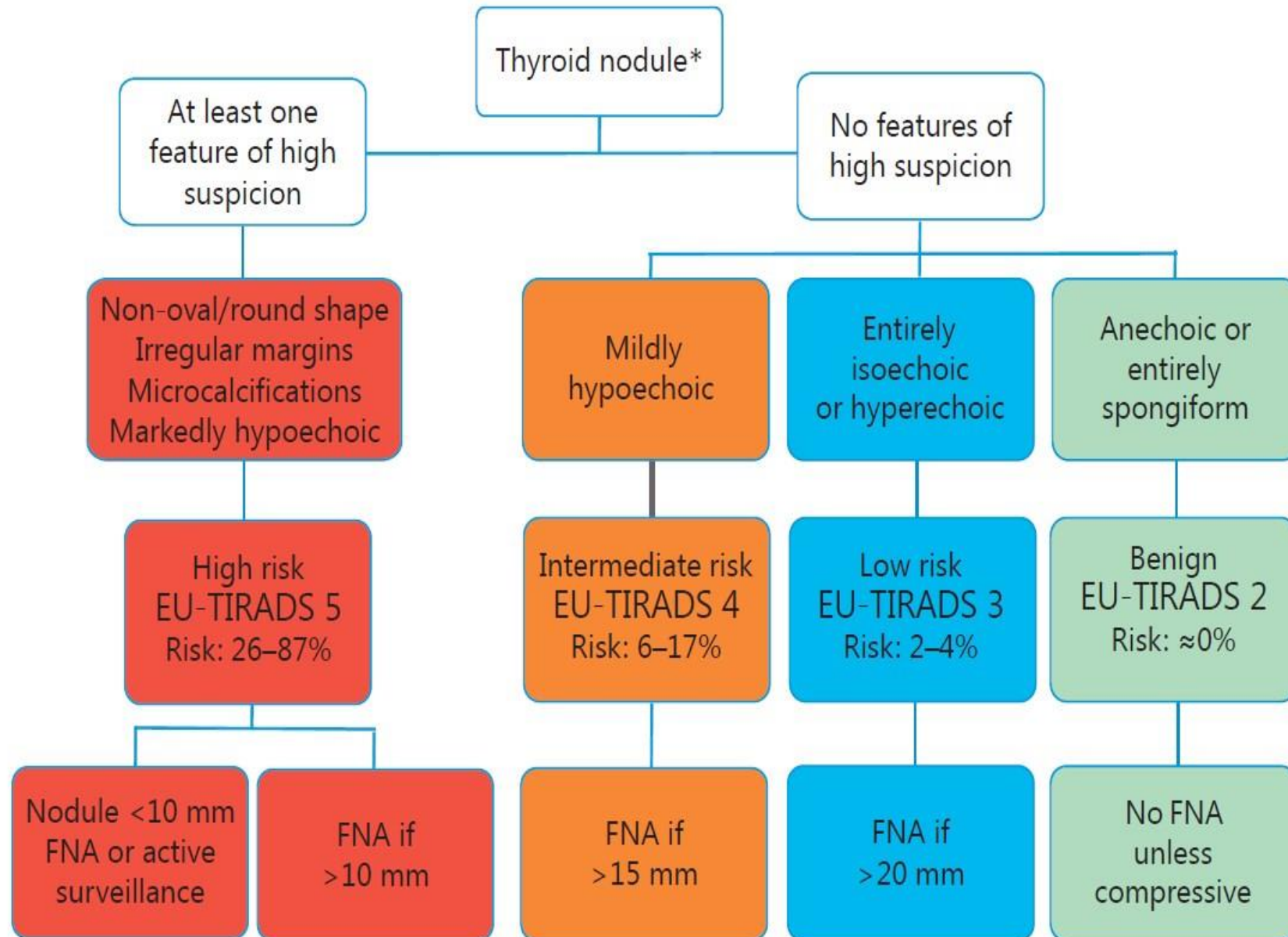
TR3
Mildly suspicious
FNA if > 2.5 cm
Follow if > 1.5 cm

4-6 points

TR4
Moderately suspicious
FNA if > 1.5 cm
Follow if > 1 cm

7 points or more

TR5
Highly suspicious
FNA if > 1 cm
Follow if > 0.5 cm



	ACR	EU
TIRADS 1	No follow-up / no FNA	-
TIRADS 2	No follow-up / no FNA	No FNA unless compressive
TIRADS 3	FNA \geq 2.5cm Follow \geq 1.5cm	FNA > 2cm
TIRADS 4	FNA \geq 1.5cm Follow \geq 1cm	FNA > 1.5cm
TIRADS 5	FNA \geq 1cm Follow \geq 0.5cm	FNA > 1cm Follow / FNA < 1cm

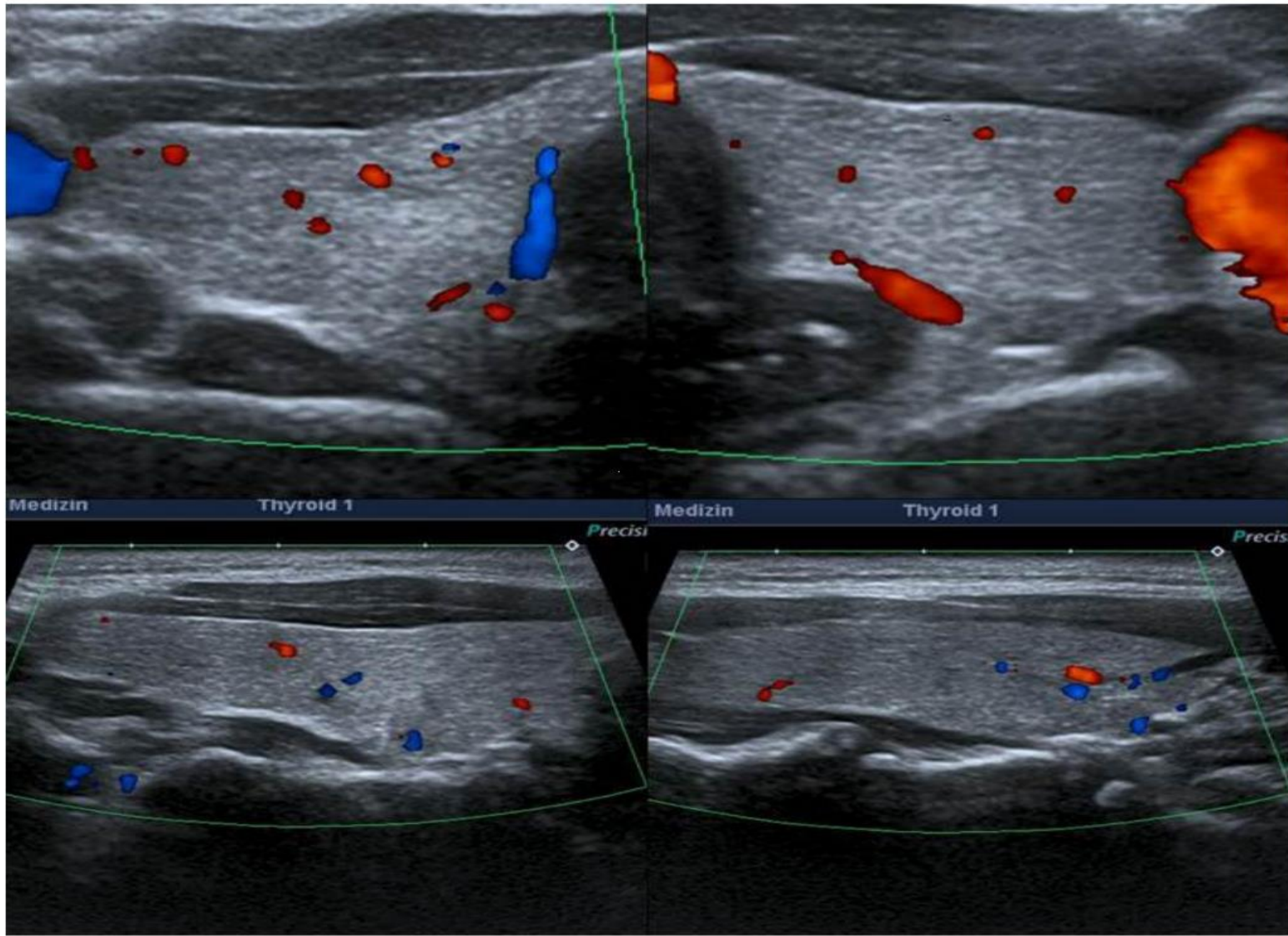


Figure 1 TI-RADS 1: normal thyroid gland.

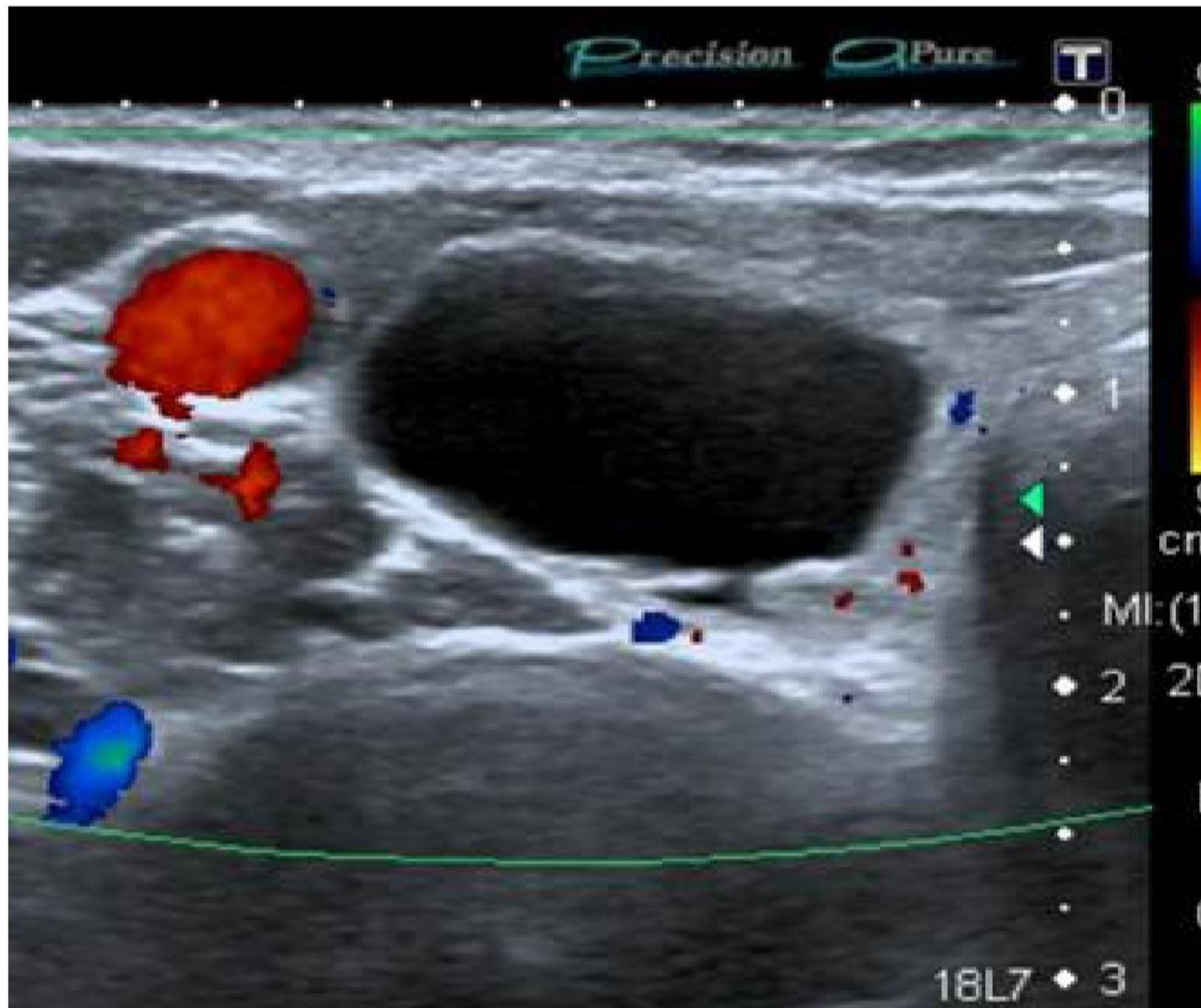


Figure 2 TI-RADS 2: simple thyroid cyst.

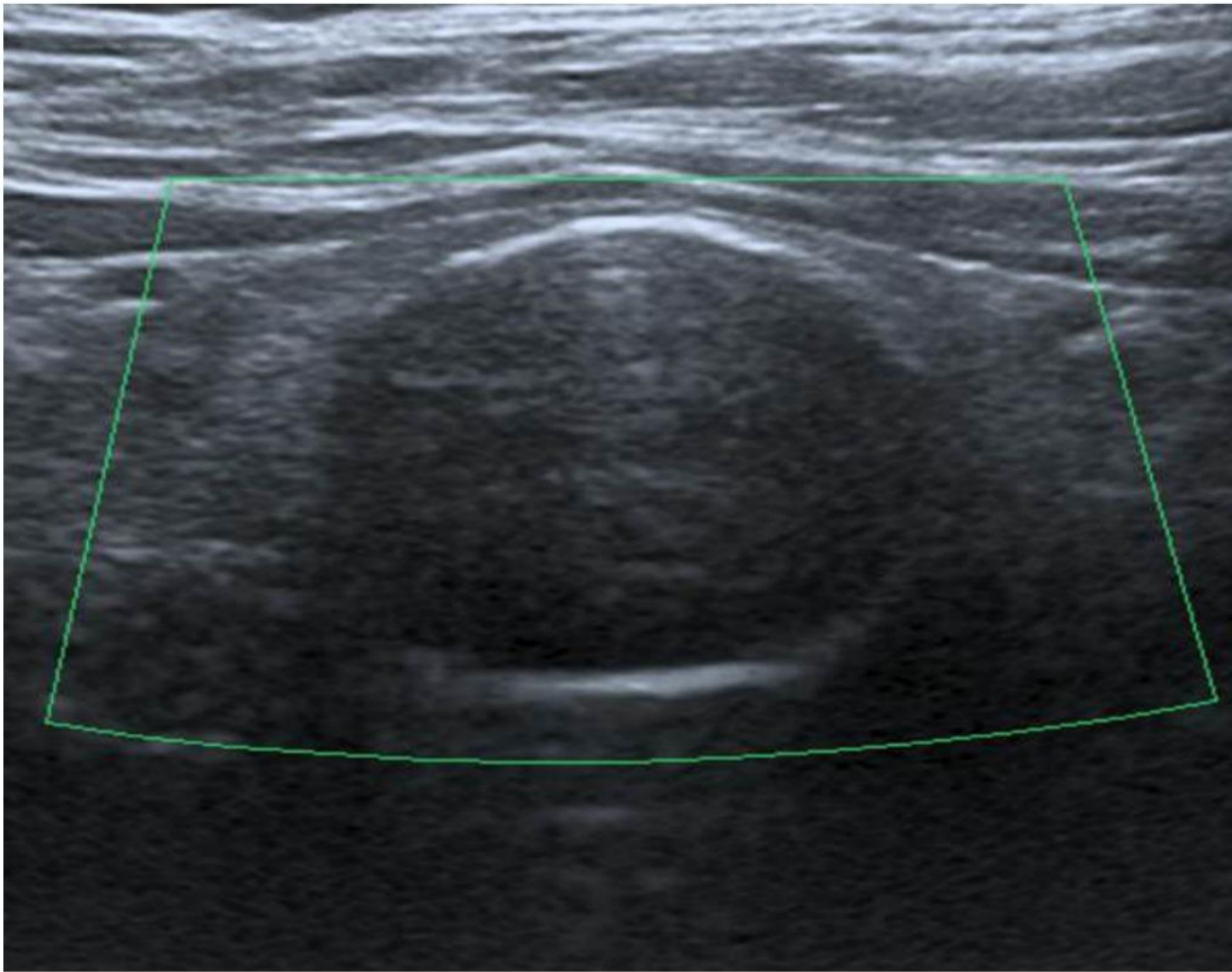


Figure 4 TI-RADS 2: nodule with homogeneous peripheral calcification.

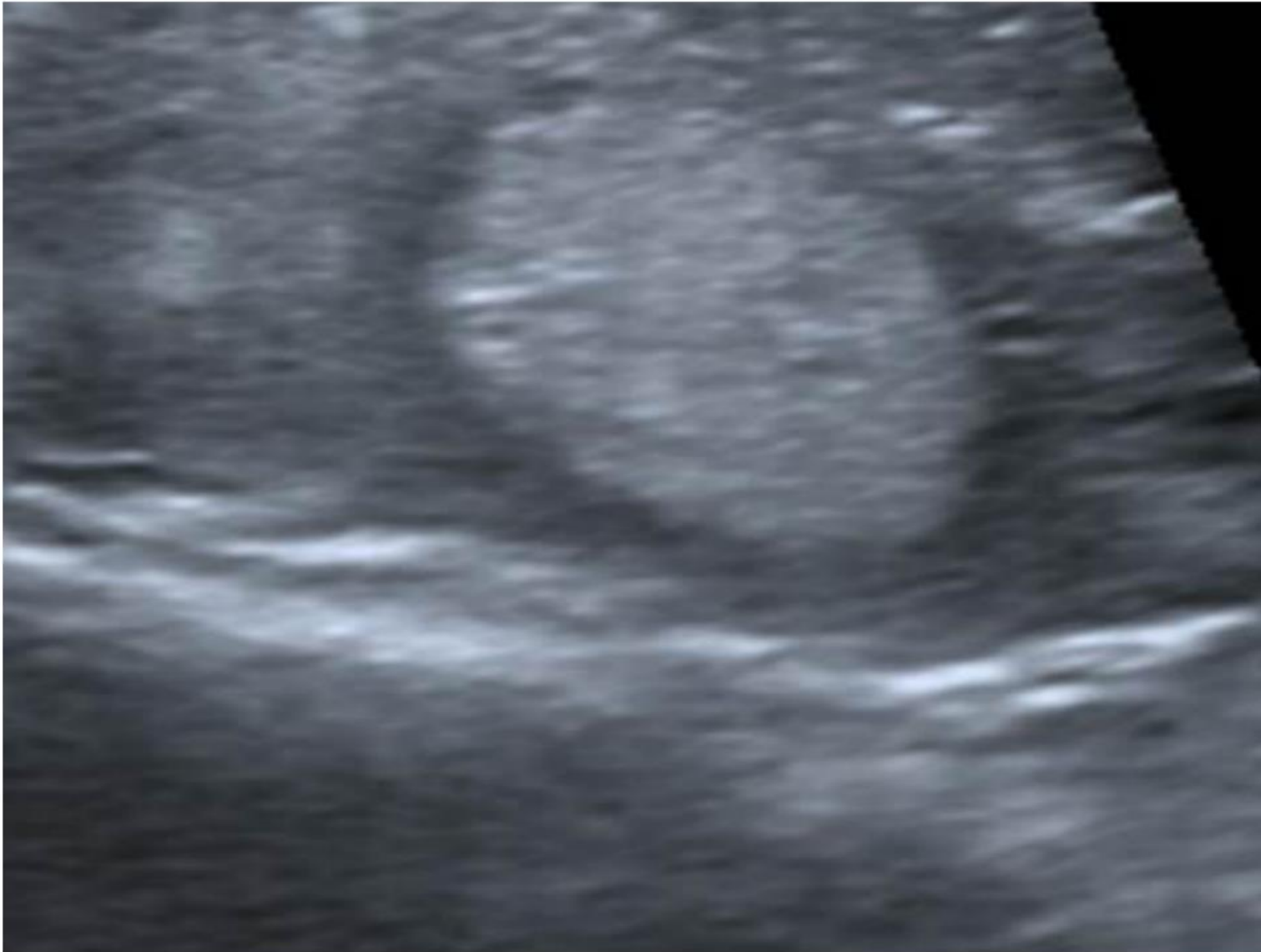

Figure 6 TI-RADS 3: hyperechoic nodule.



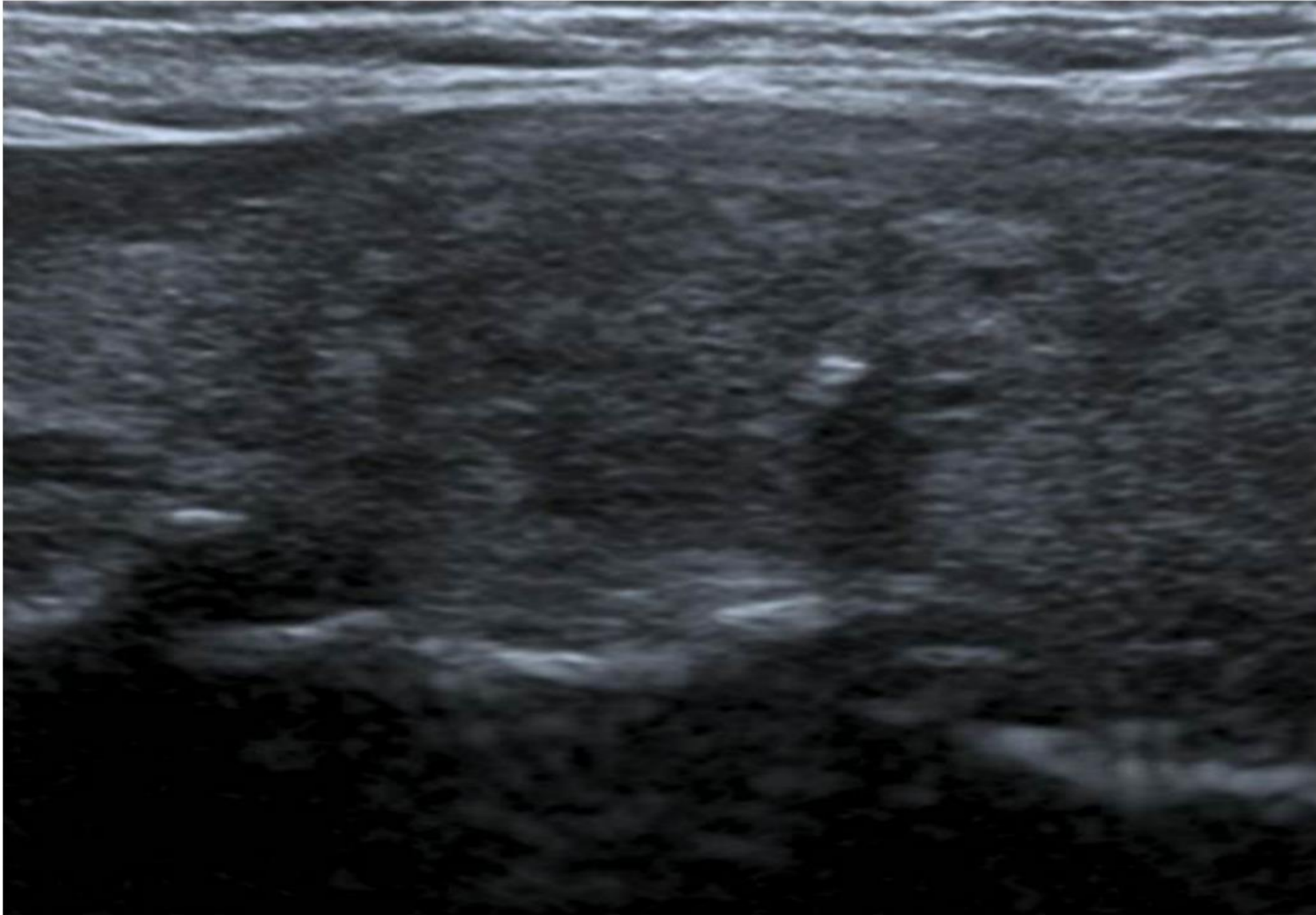


Figure 12 TI-RADS 4b: nodule with microcalcifications and poorly defined irregular margins. Score of 2.

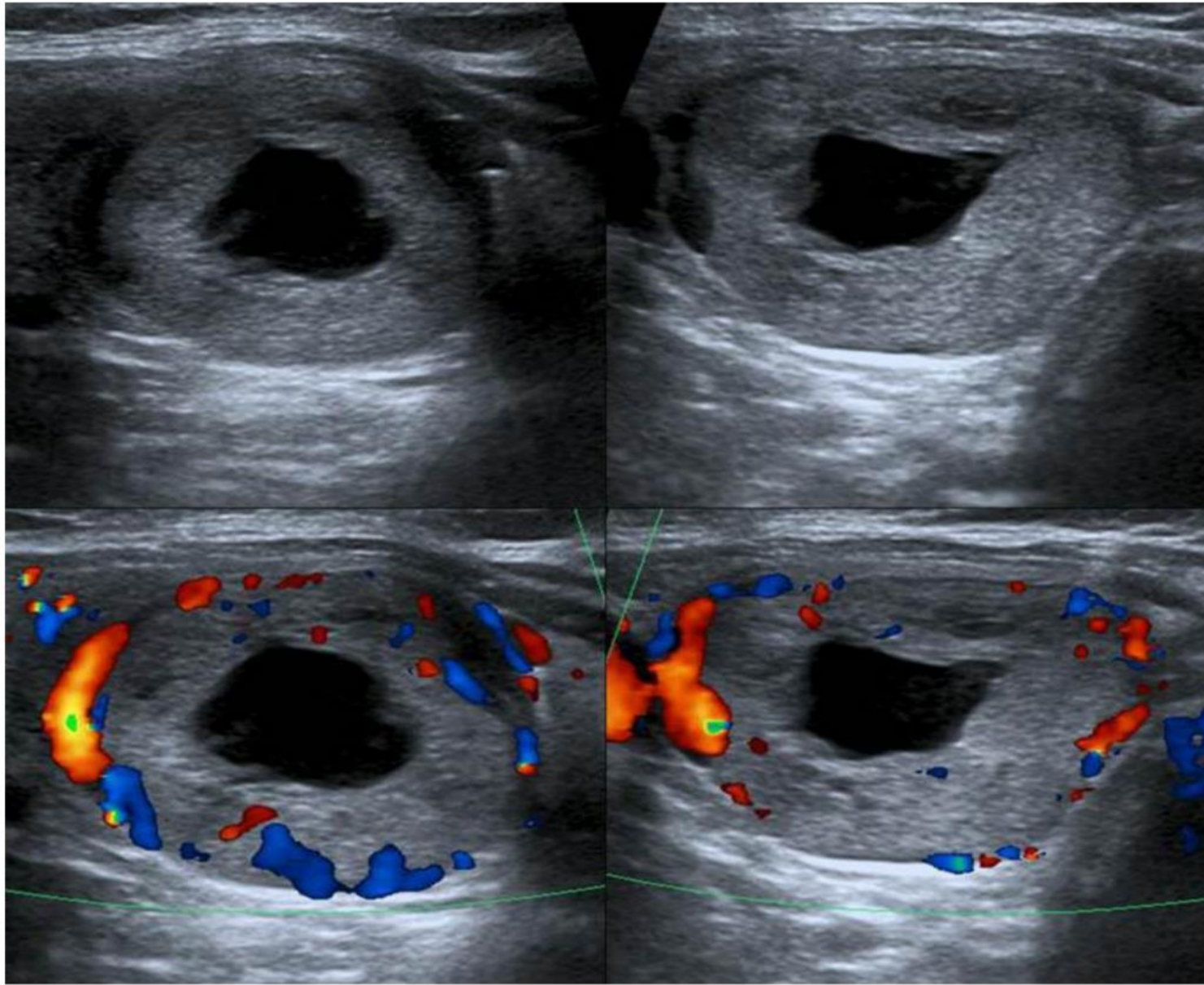


Figure 3 TI-RADS 2: solid nodule with central cyst.

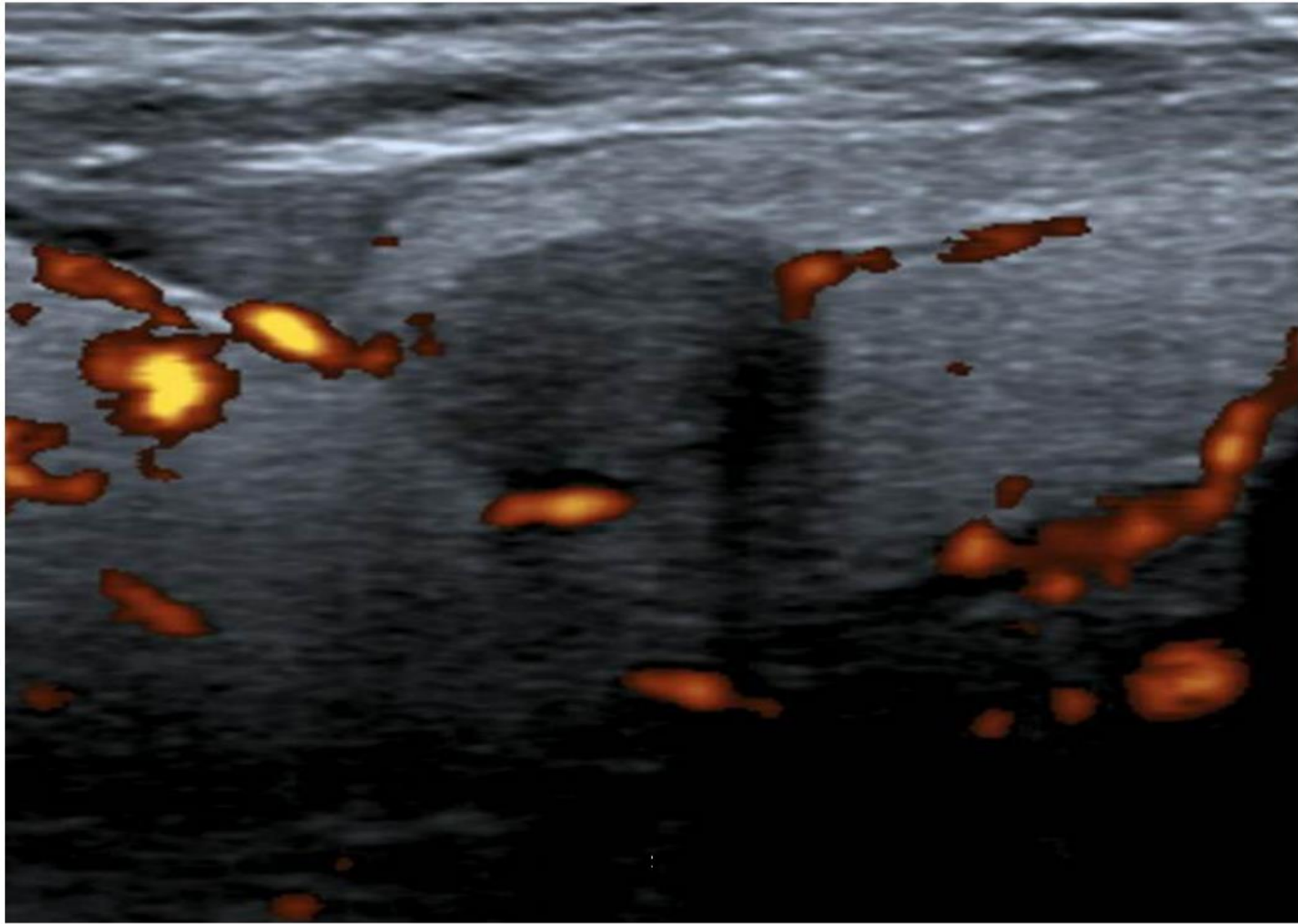


Figure 11 TI-RADS4a: markedly hypoechoic nodule, of normal shape and abnormal vascularity. Score of 1.

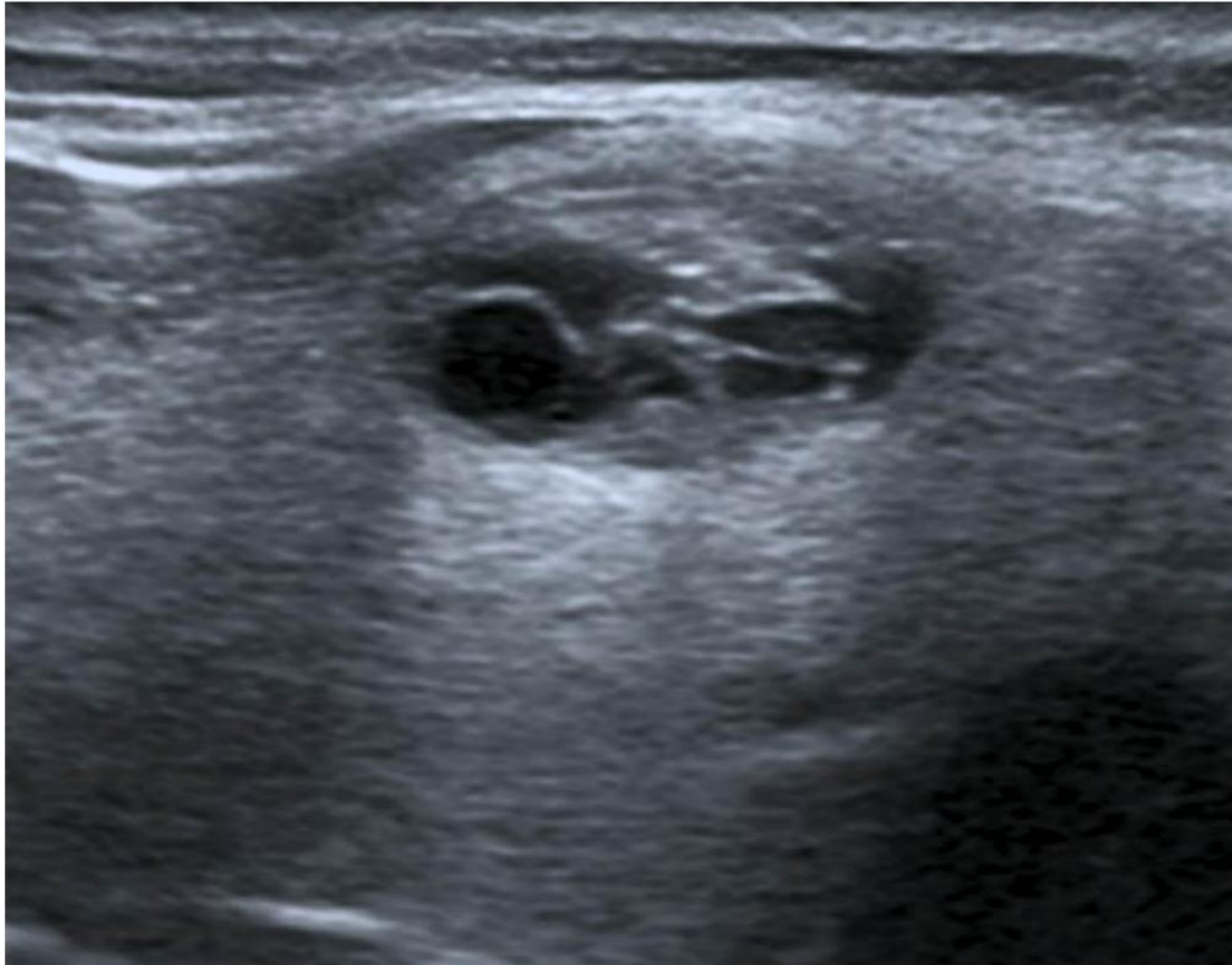

Figure 5 TI-RADS 2: spongiform nodule.

TABLE 6. SONOGRAPHIC PATTERNS, ESTIMATED RISK OF MALIGNANCY, AND FINE-NEEDLE ASPIRATION GUIDANCE FOR THYROID NODULES

<i>Sonographic pattern</i>	<i>US features</i>	<i>Estimated risk of malignancy, %</i>	<i>FNA size cutoff (largest dimension)</i>
High suspicion	Solid hypoechoic nodule or solid hypoechoic component of a partially cystic nodule with one or more of the following features: irregular margins (infiltrative, microlobulated), microcalcifications, taller than wide shape, rim calcifications with small extrusive soft tissue component, evidence of ETE	>70–90 ^a	Recommend FNA at ≥1 cm
Intermediate suspicion	Hypoechoic solid nodule with smooth margins without microcalcifications, ETE, or taller than wide shape	10–20	Recommend FNA at ≥1 cm
Low suspicion	Isoechoic or hyperechoic solid nodule, or partially cystic nodule with eccentric solid areas, without microcalcification, irregular margin or ETE, or taller than wide shape.	5–10	Recommend FNA at ≥1.5 cm
Very low suspicion	Spongiform or partially cystic nodules without any of the sonographic features described in low, intermediate, or high suspicion patterns	<3	Consider FNA at ≥2 cm Observation without FNA is also a reasonable option
Benign	Purely cystic nodules (no solid component)	<1	No biopsy ^b

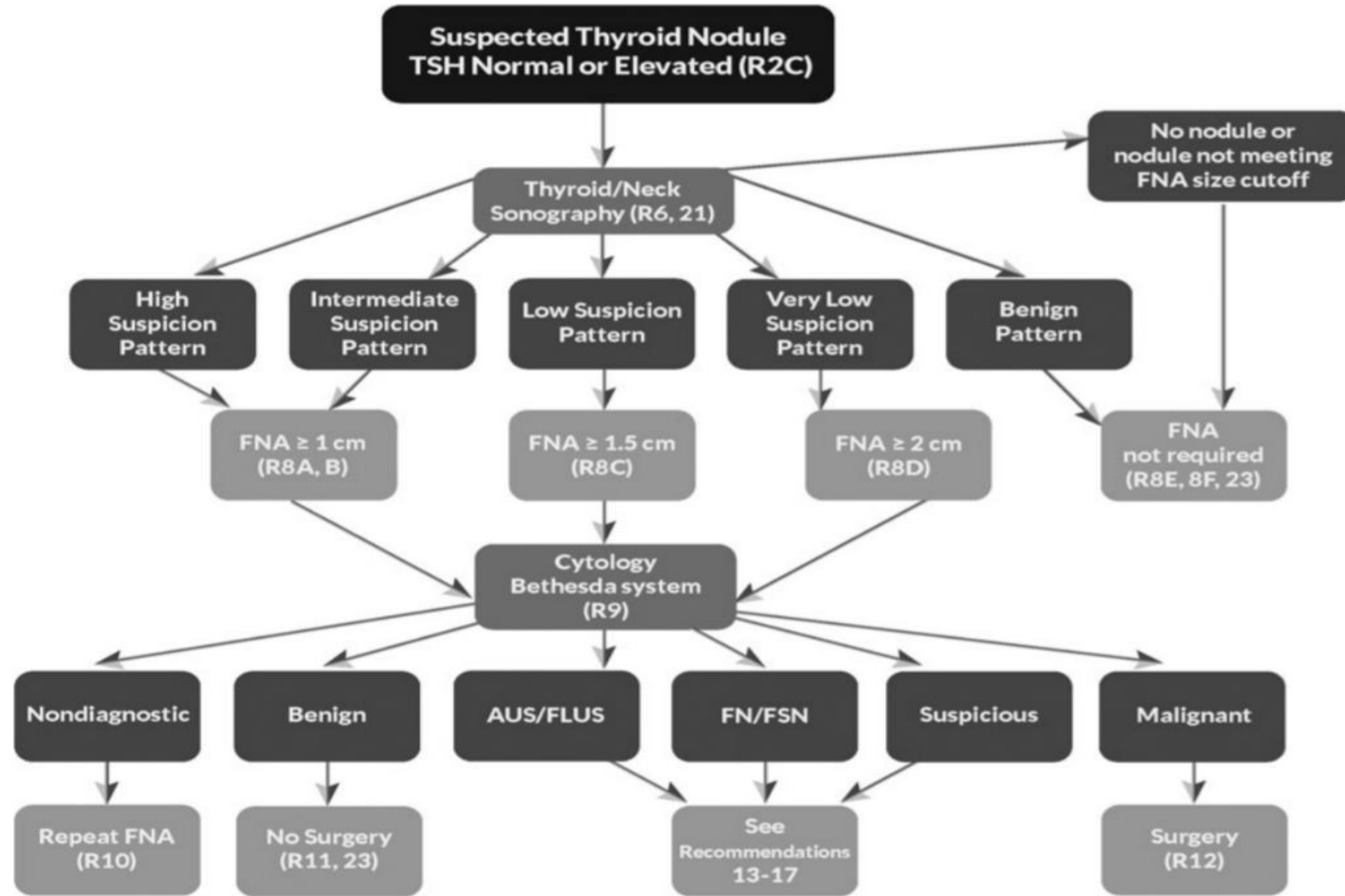
US-guided FNA is recommended for cervical lymph nodes that are sonographically suspicious for thyroid cancer (see Table 7).

^aThe estimate is derived from high volume centers, the overall risk of malignancy may be lower given the interobserver variability in sonography.

^bAspiration of the cyst may be considered for symptomatic or cosmetic drainage.

ETE, extrathyroidal extension.

THYROID NODULE/DTC GUIDELINES



1. Algorithm for evaluation and management of patients with thyroid nodules based on US pattern and cytology. R, recommendation in text.

Although the sensitivities are significantly lower for any single variable, the overall predictive value for malignancy in multivariate logistic regression

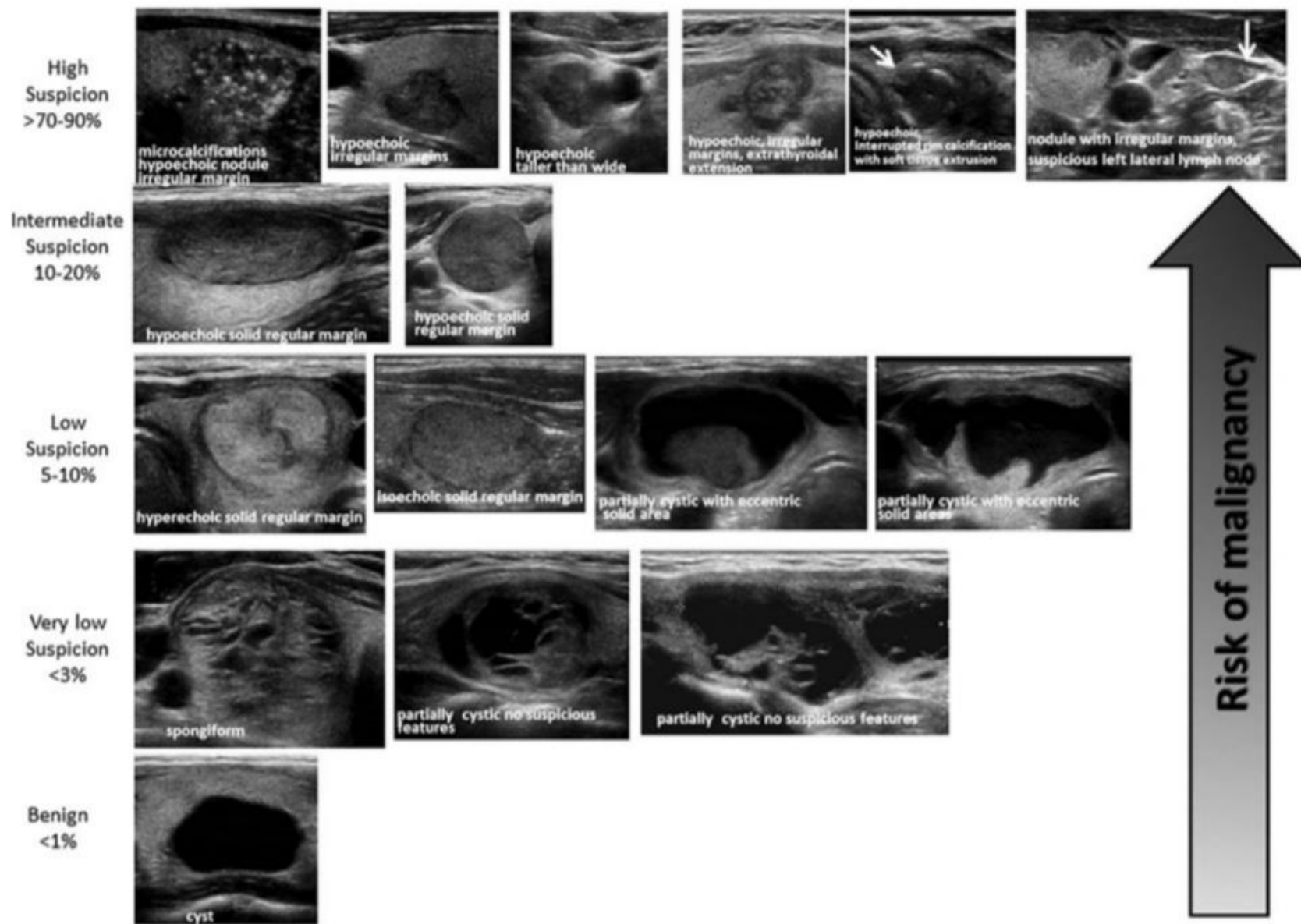
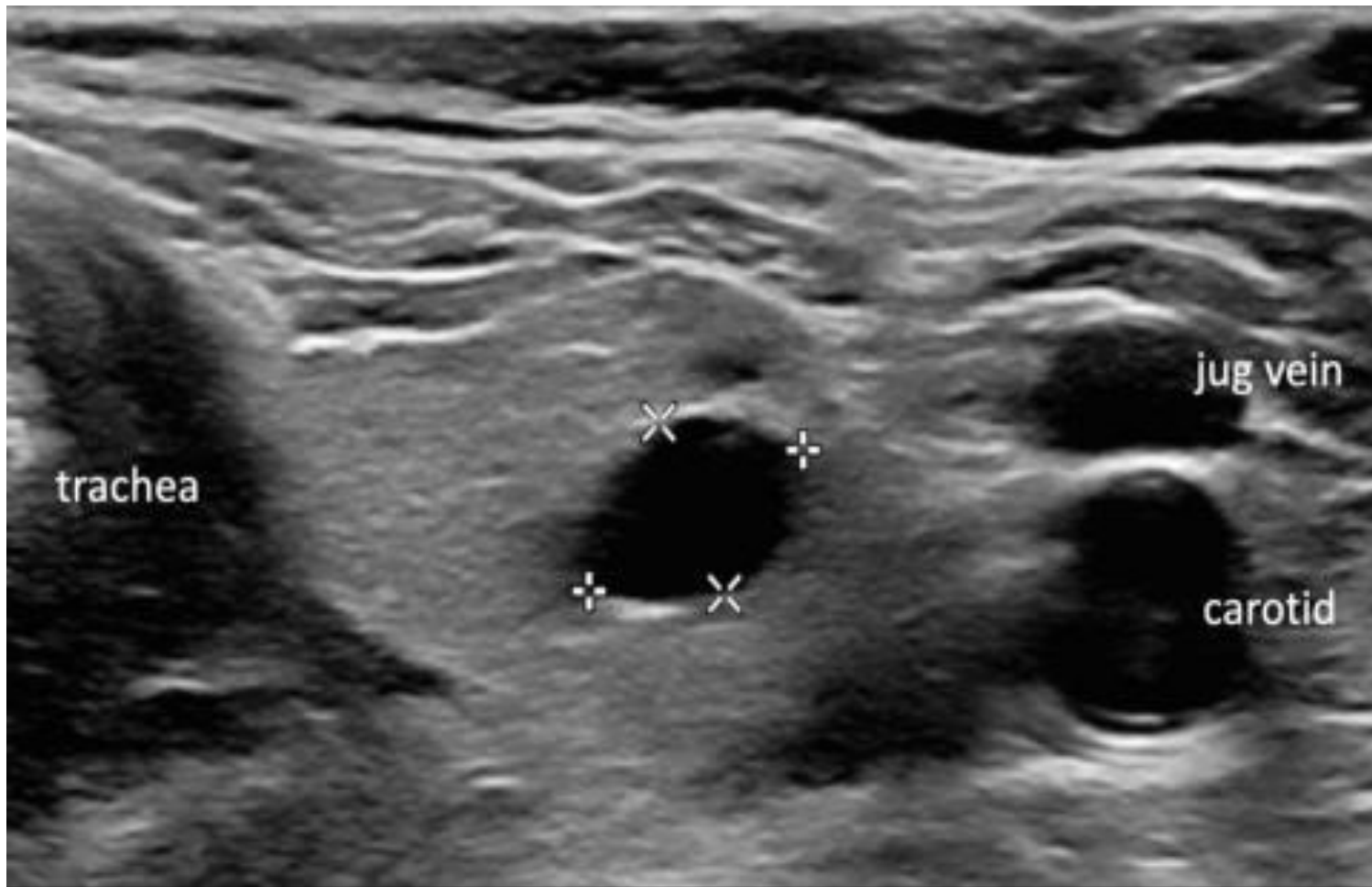


FIG. 2. ATA nodule sonographic patterns and risk of malignancy.

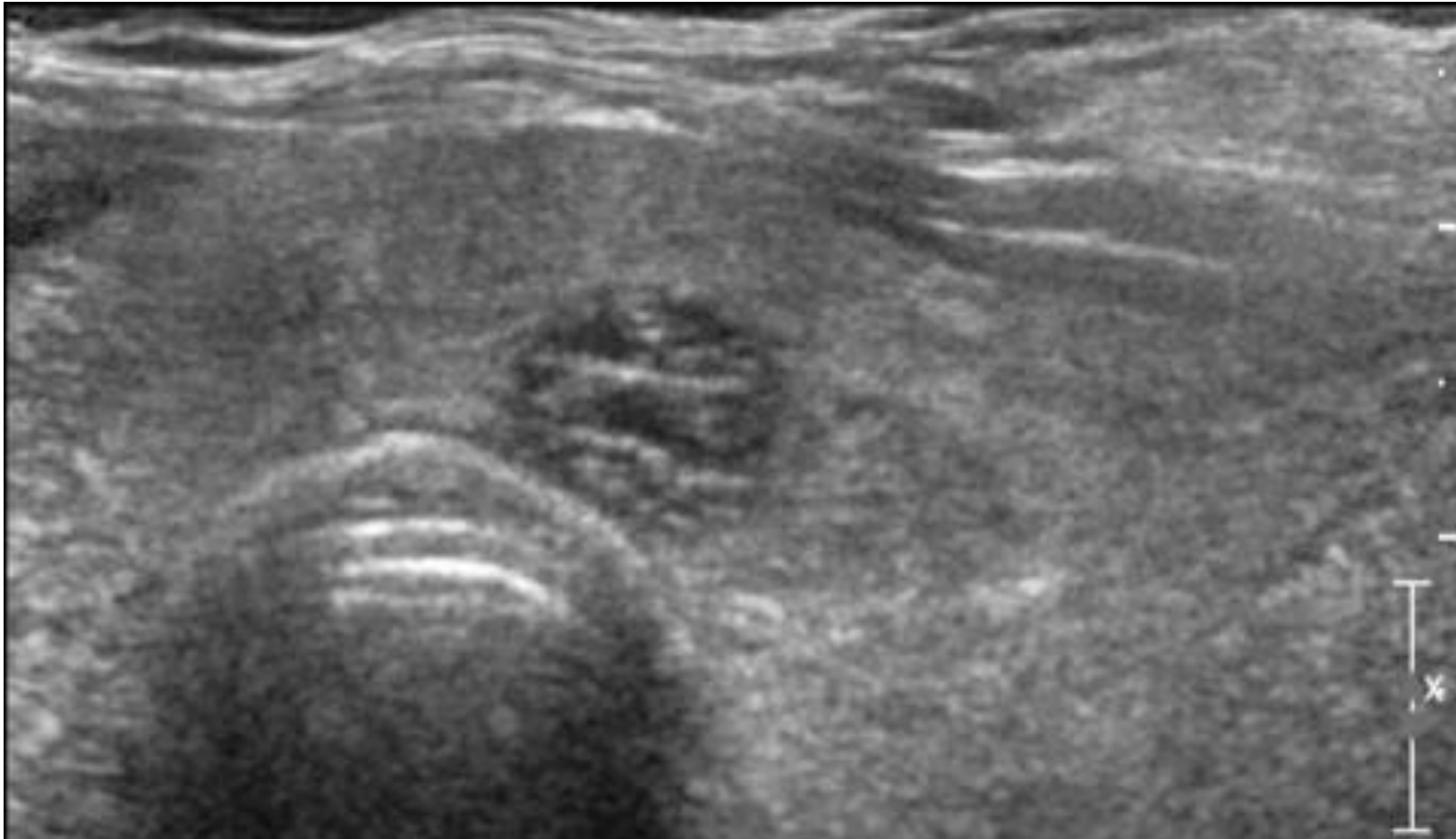


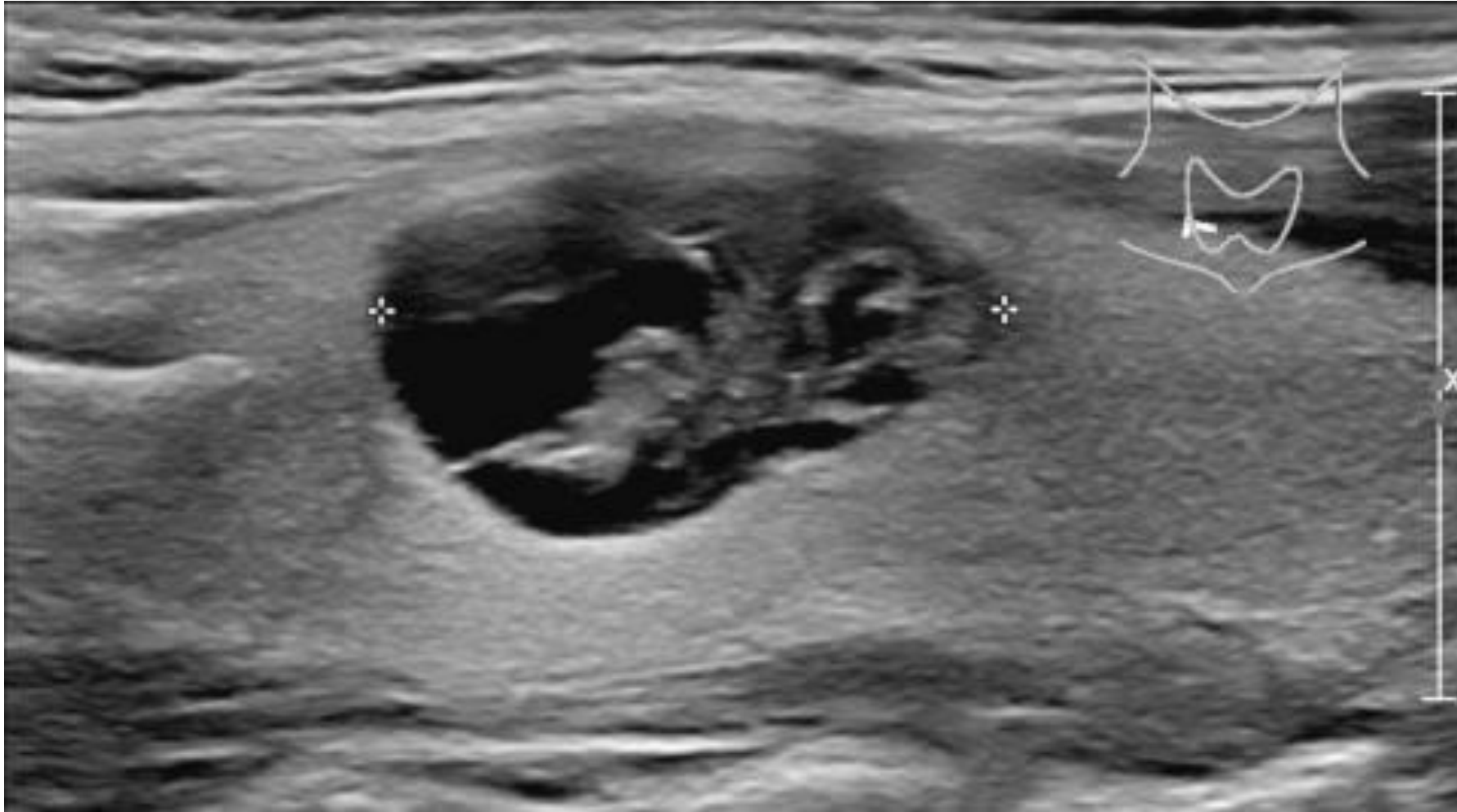Cyst

Here a typical cyst.

No further evaluation is needed

Spongiform nodules have a sponge-like appearance, with at least 50% cystic composition of tiny cystic parts. No further characterization is needed.





Mixed cystic/solid

In mixed cystic/solid lesions the amount of cystic and solid parts is not important.

This lesion gets 1 point for the mixed cystic/solid composition

Solid lesions

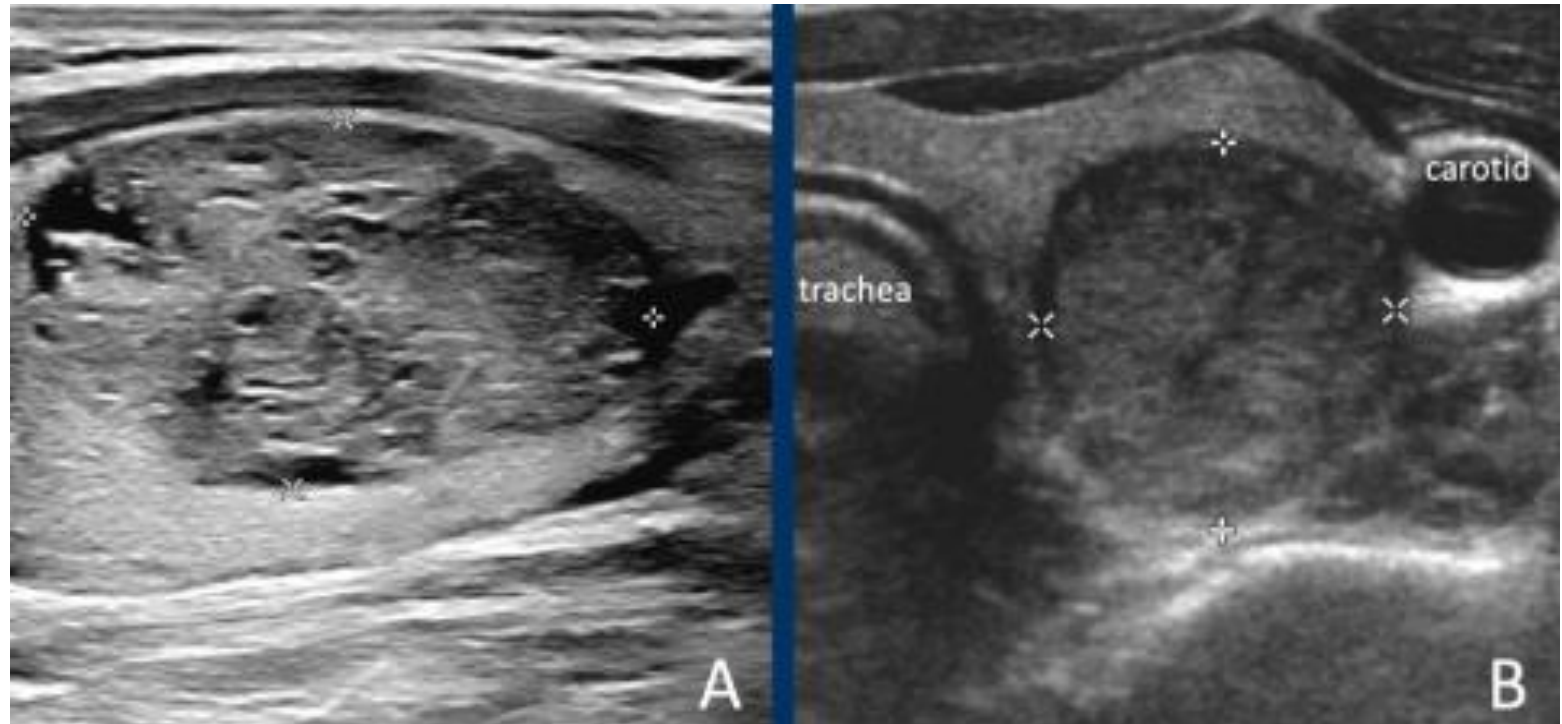The lesion in A is almost completely solid.

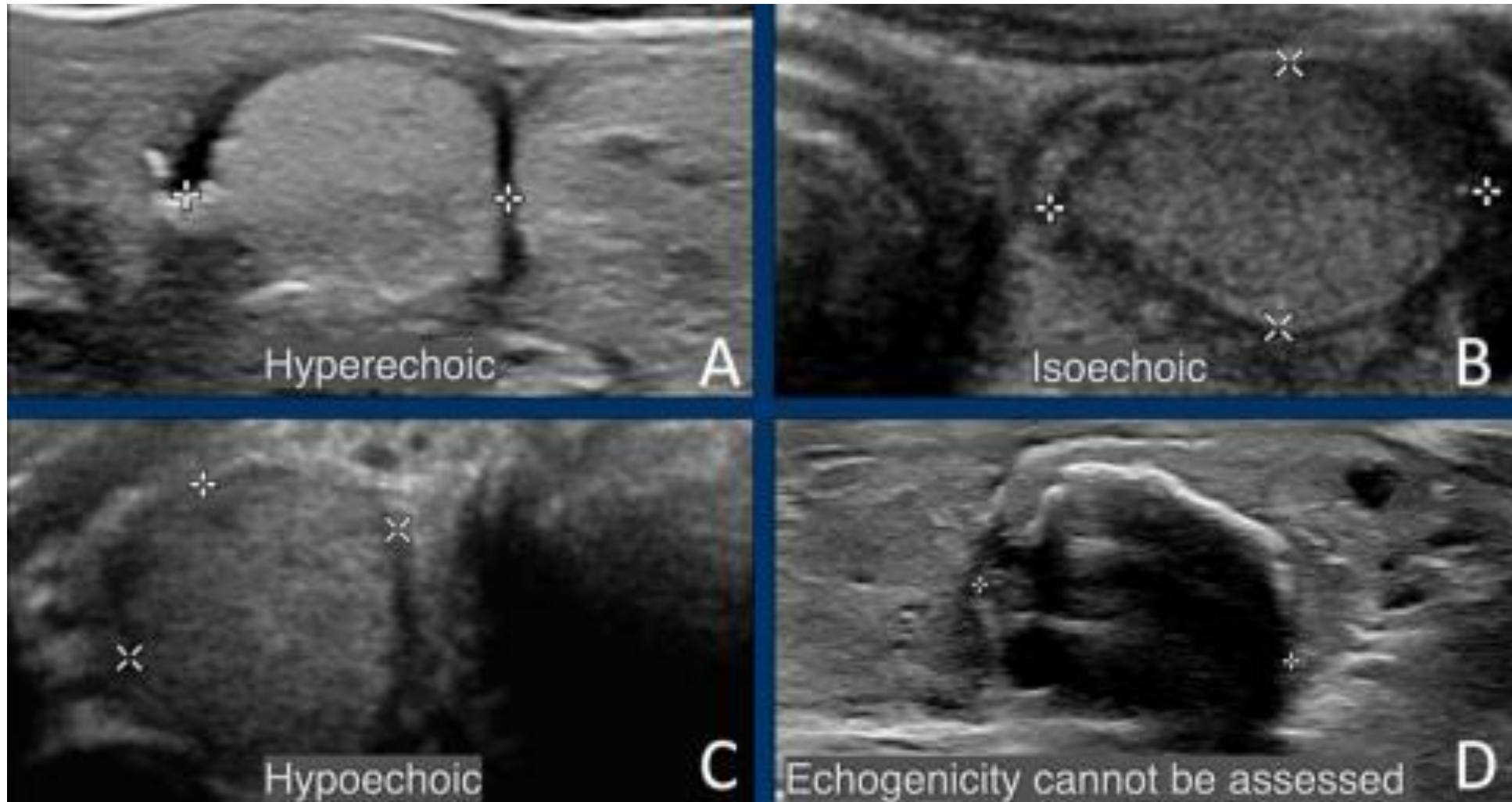
While there are small cystic parts, it is not considered a spongiform nodule, because the small cystic parts are far less than 50% of the total nodule.

The lesion in B is completely solid.

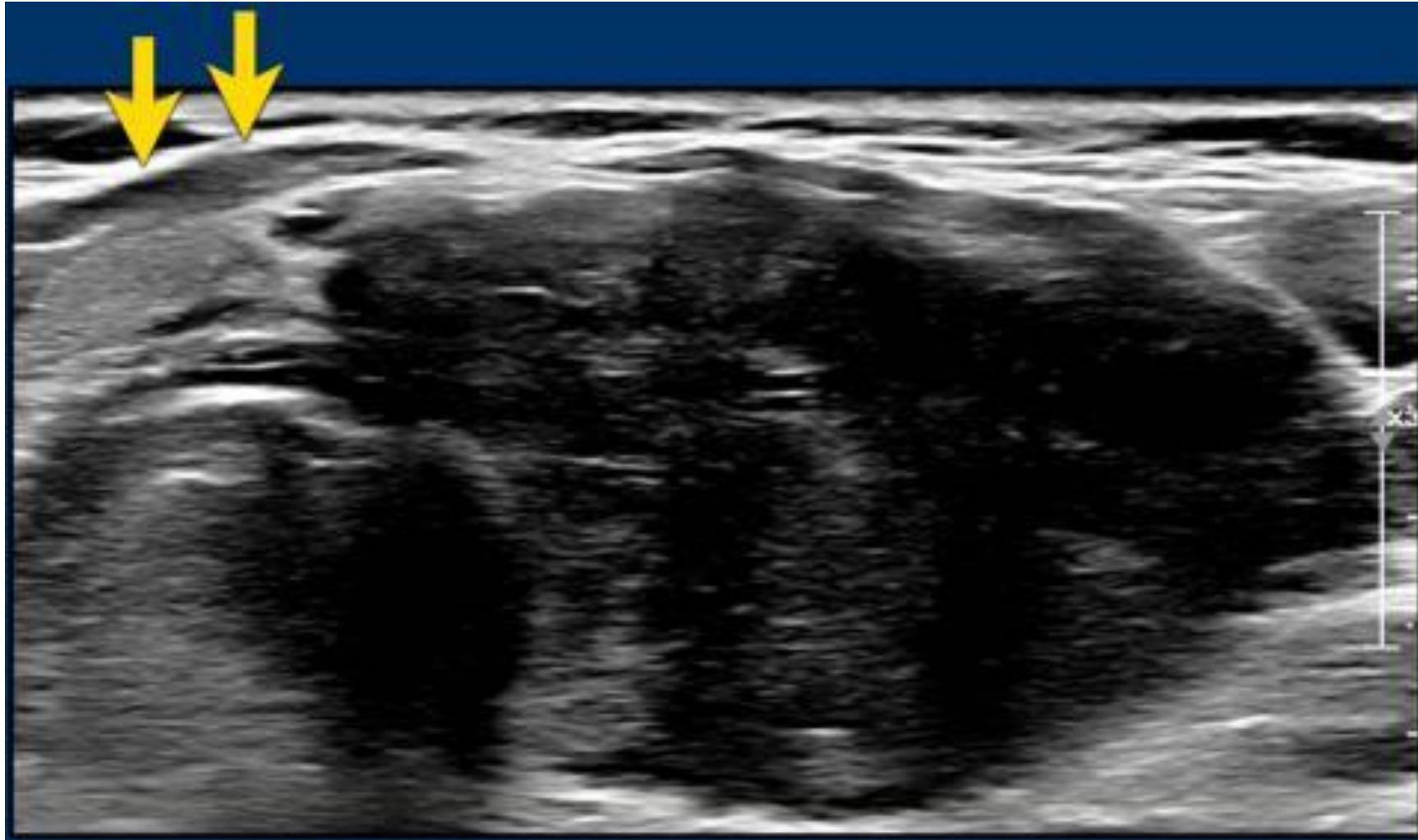
In solid nodules at least 95% of the nodule should be solid.

This percentage should be an estimation, it is not needed to calculate this.





Hypoechoic means that a lesion is more hypoechoic than normal thyroid parenchyma.
If the echogenicity cannot be assessed, for example because of calcifications, 1 point is given for the echogenicity



Very hypoechoic , i.e. 3 points in TI-RADS.

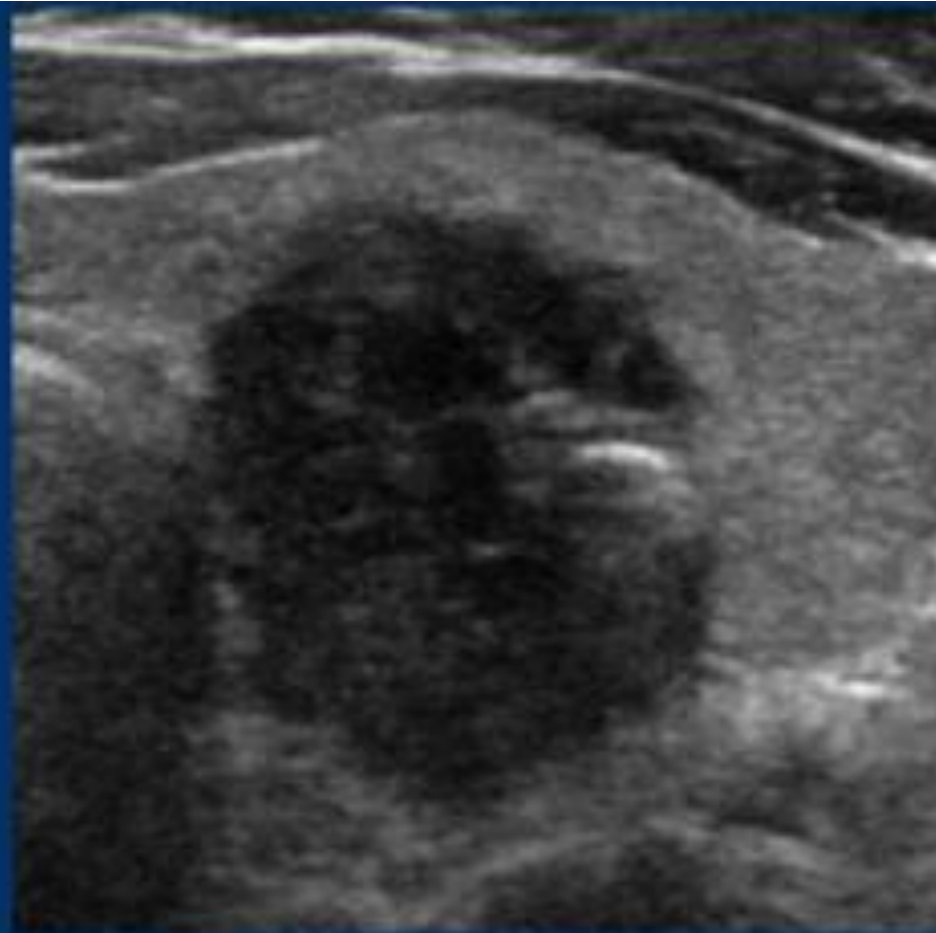
A very hypoechoic lesion is more hypoechoic than normal muscle.
Notice that the tumor is more hypoechoic in comparison to the strap muscles (arrows)

SHAPE

(choose 1)

Wider-than-tall 0

Taller-than-wide 3



Taller than wide

The shape should be assessed in the axial plane. A taller-than-wide shape is a strong predictor of malignancy, and therefore gets 3 points.

MARGIN

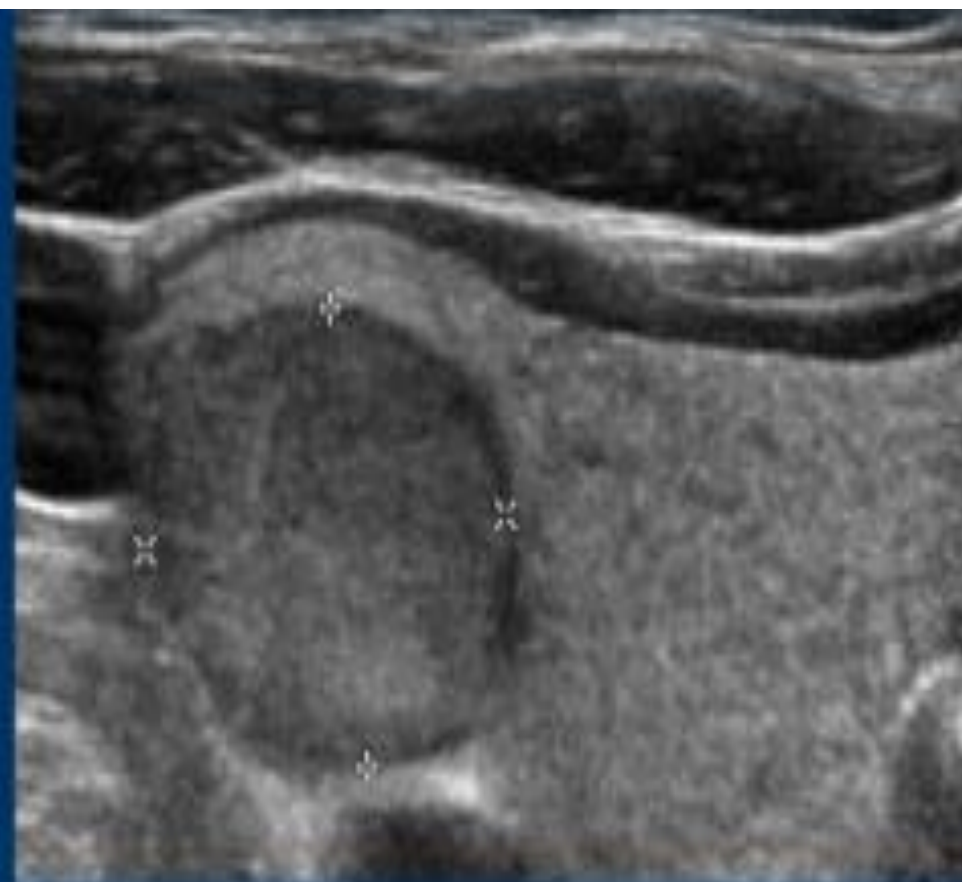
(choose 1)

Smooth 0

Ill-defined 0

Lobulated or irregular 2

Extra-thyroidal extention 3



Smooth margin

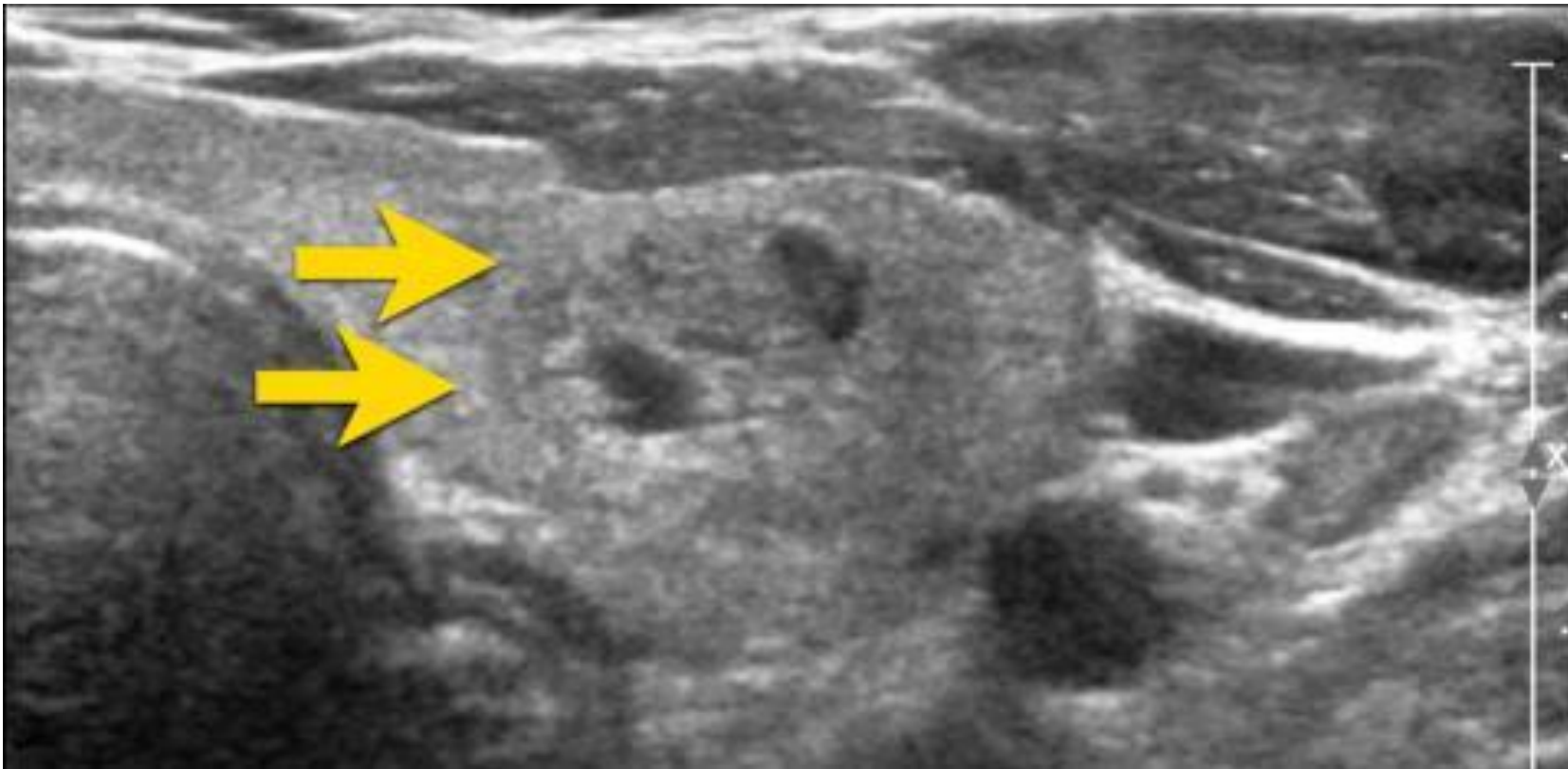
- The margin is often best assessed on the anterior side.
- **Smooth**: the margin is completely smooth
- **Ill-defined**: the margins of the nodule cannot be clearly defined from the thyroid parenchyma. This is a benign feature and should be distinguished from the irregular margin.
- **Lobulated or irregular**: margins are lobulated, spiculated, irregular or angulated.
- **Extra-thyroidal extension**: difficult to analyze on ultrasound, there should be clear invasion of nearby structures. Bulging of the nodule in nearby structures is not enough

Ill-defined nodule.

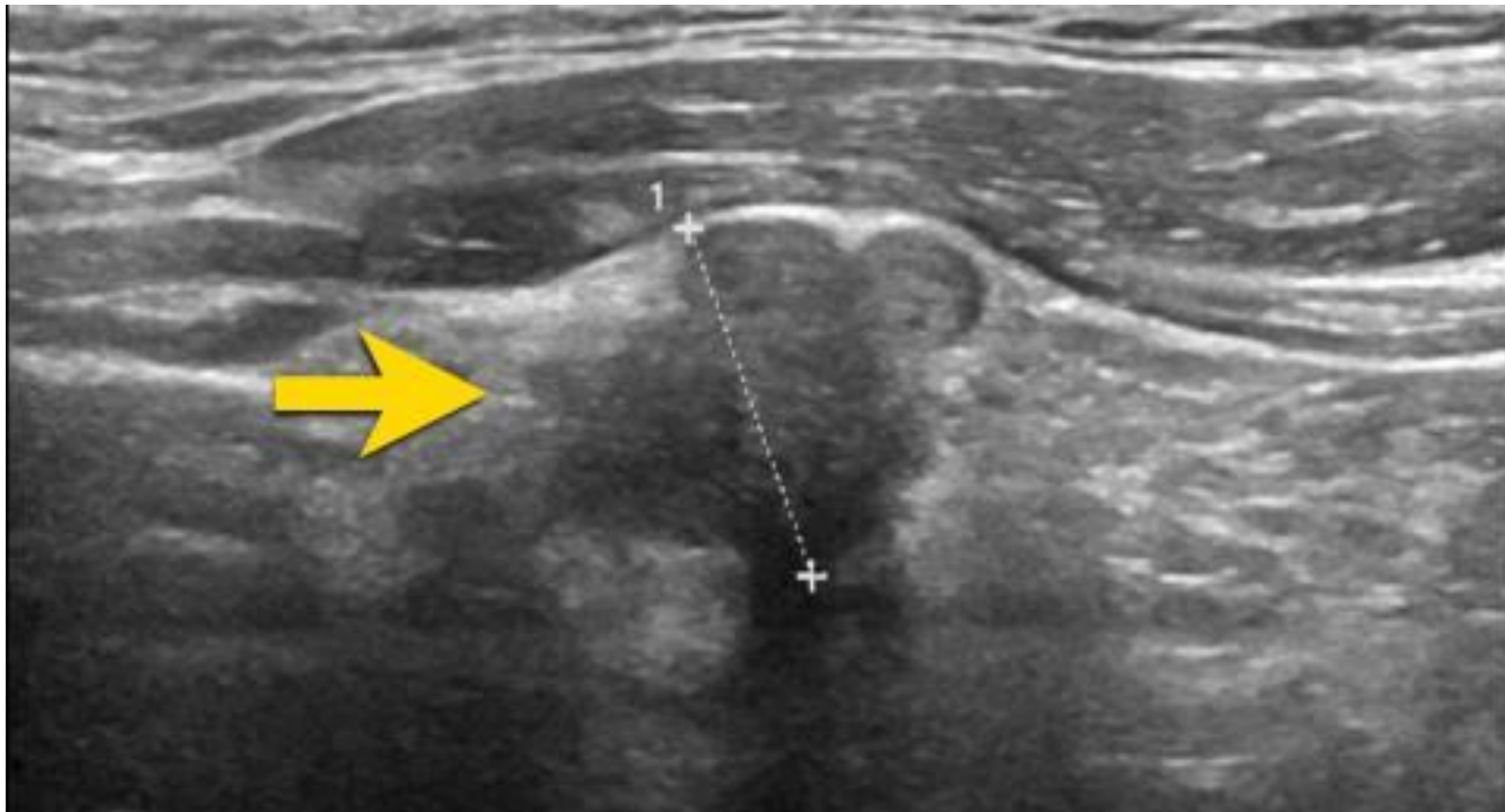
Notice how only some small parts of the border of the nodule can be defined (arrow).

Most of its margin is indistinct from the thyroid parenchyma.

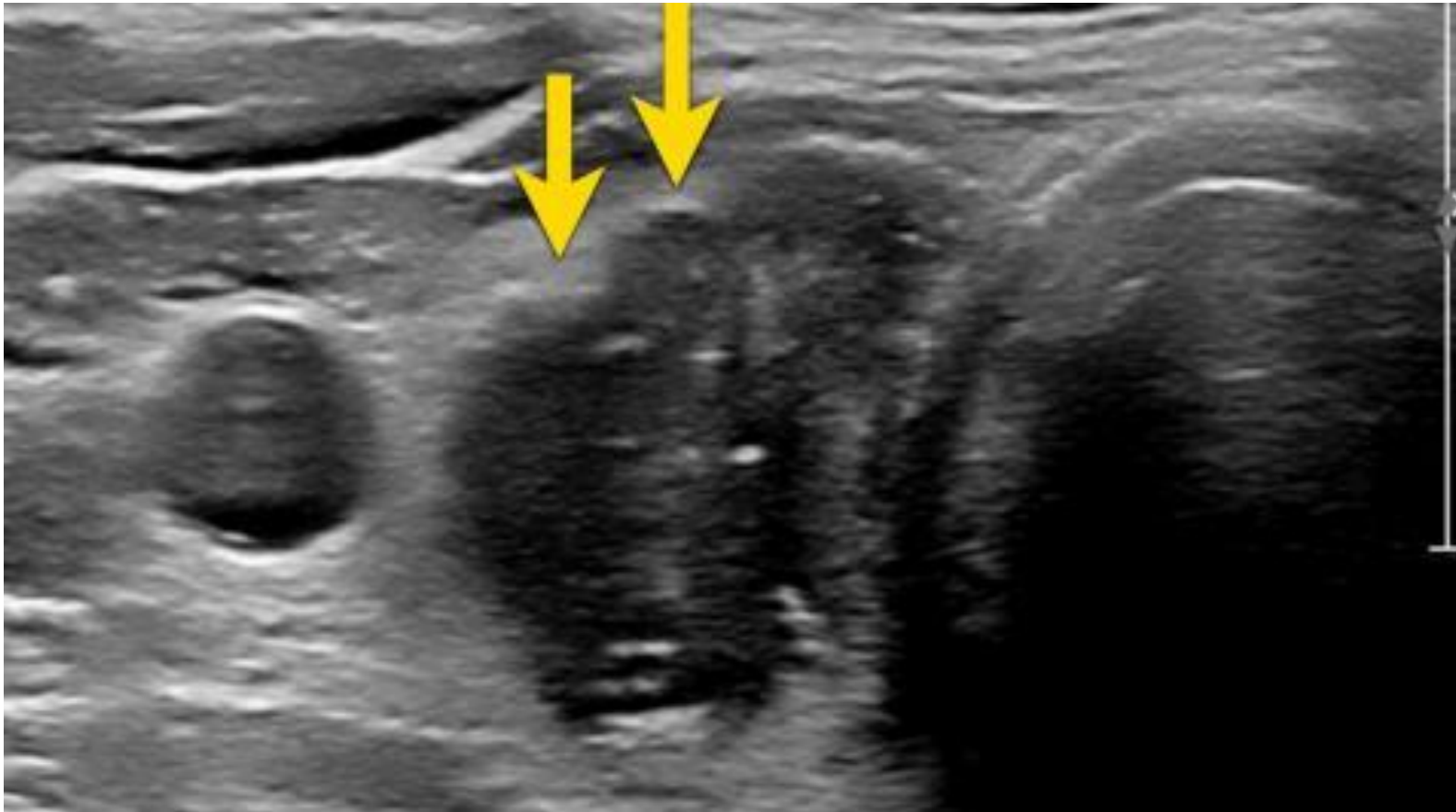0 points in TI-RADS



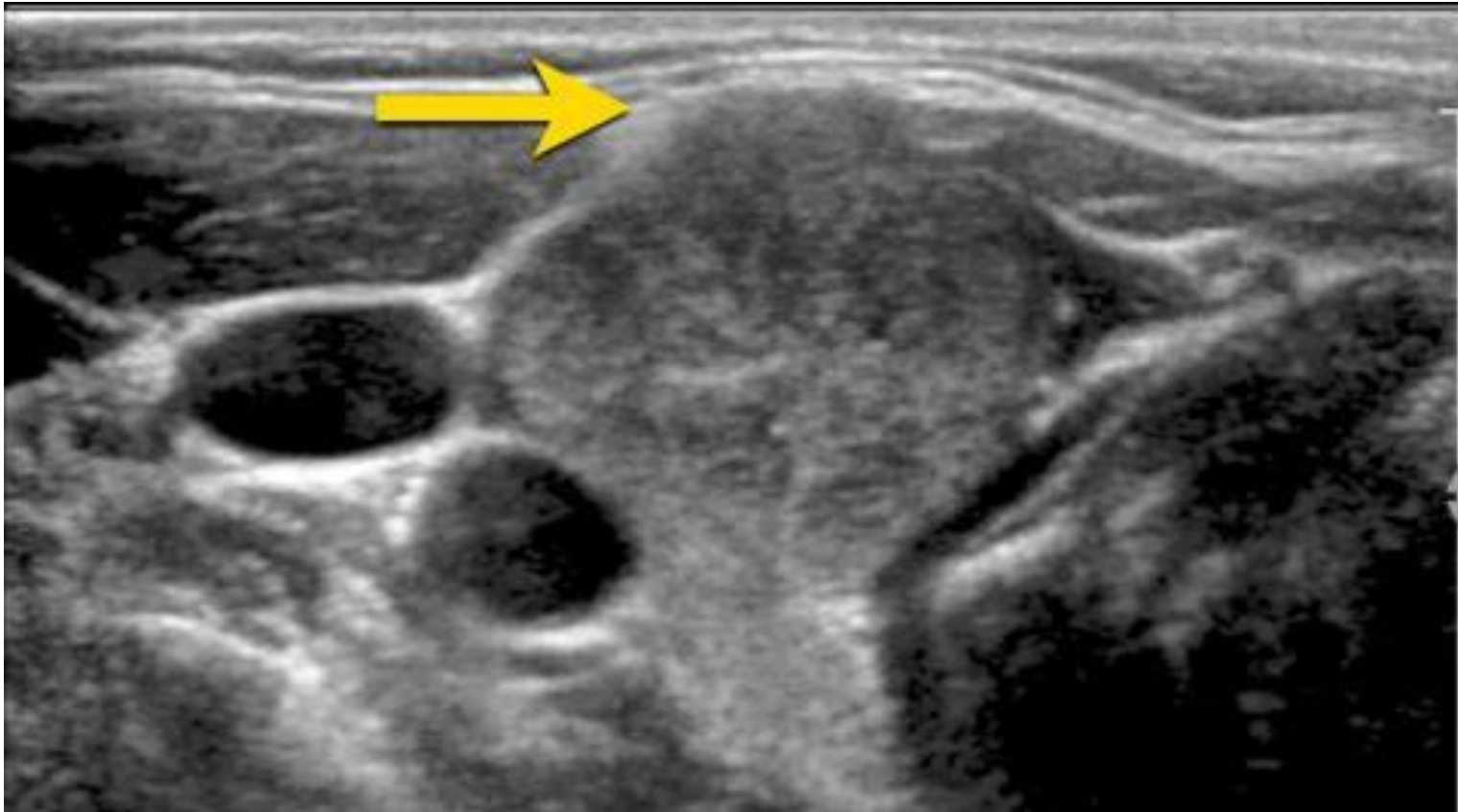
A nodule with irregular angulated margins.
2 points in TI-RADS



The image shows an irregular lobulated margin of the anterior surface.
2 points in TI-RADS



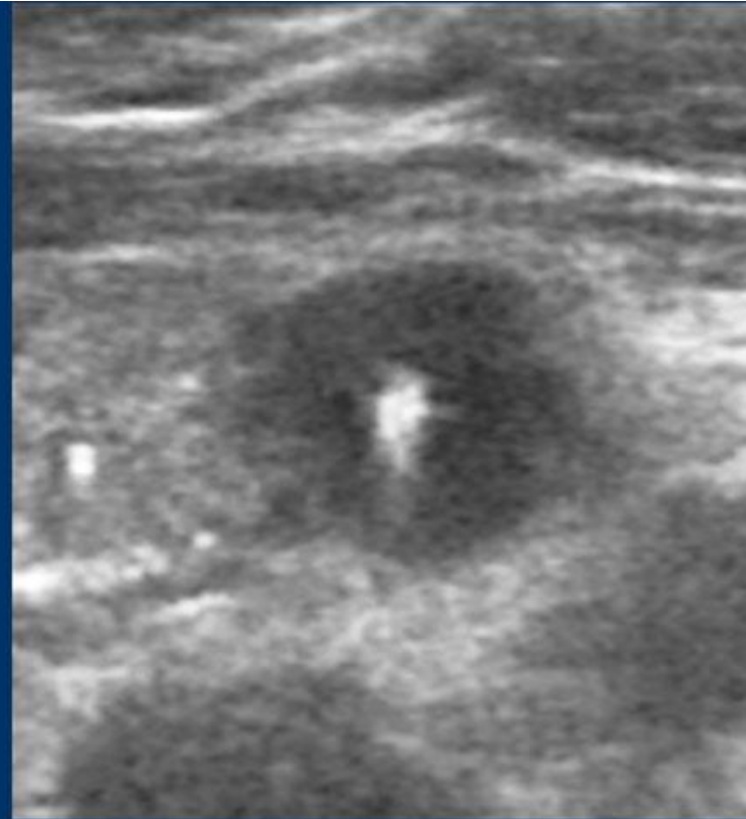
There is a nodule which has exophytic growth with compression of the nearby structures. However, there is no frank invasion, therefore this does not classify as extra thyroidal extension.



ECHOGENIC FOCI

(choose all that apply)

None or large comet-tail artifacts	0
Macrocalcifications	1
Peripheral (rim) calcifications	2
Punctate echogenic foci	3



Large comet-tail artefact

Comet tail artefact

Echogenic foci is the only category where multiple options are possible and you have to choose all that apply.

Points will be added to the total score.

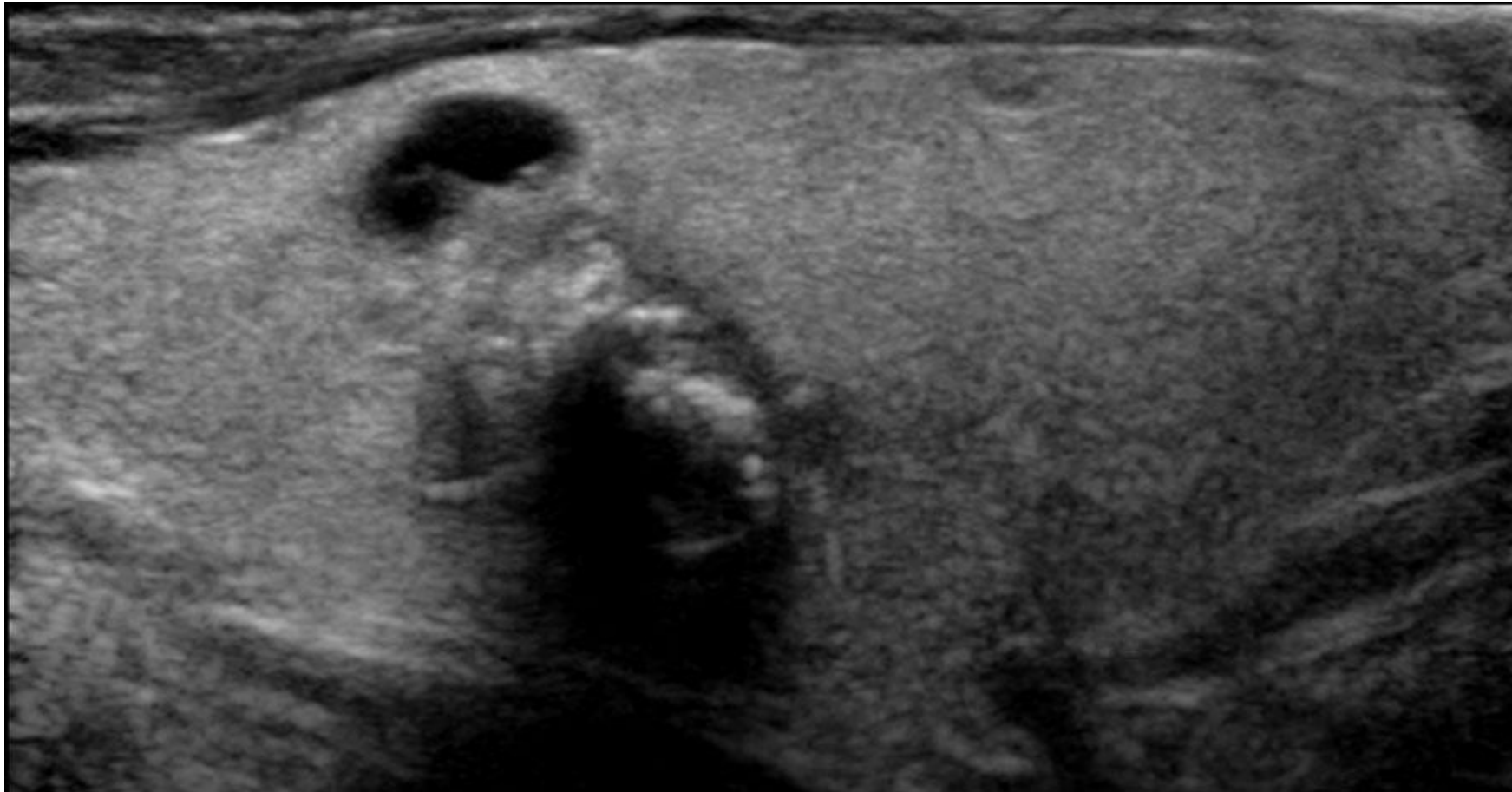
This means that when both punctate echogenic foci and rim calcifications are present, the TI-RADS points are $2 + 1 = 3$ points
0 points is given for:

- No echogenic foci.
- Large comet tail artefacts > 1 mm.

Macrocalcification

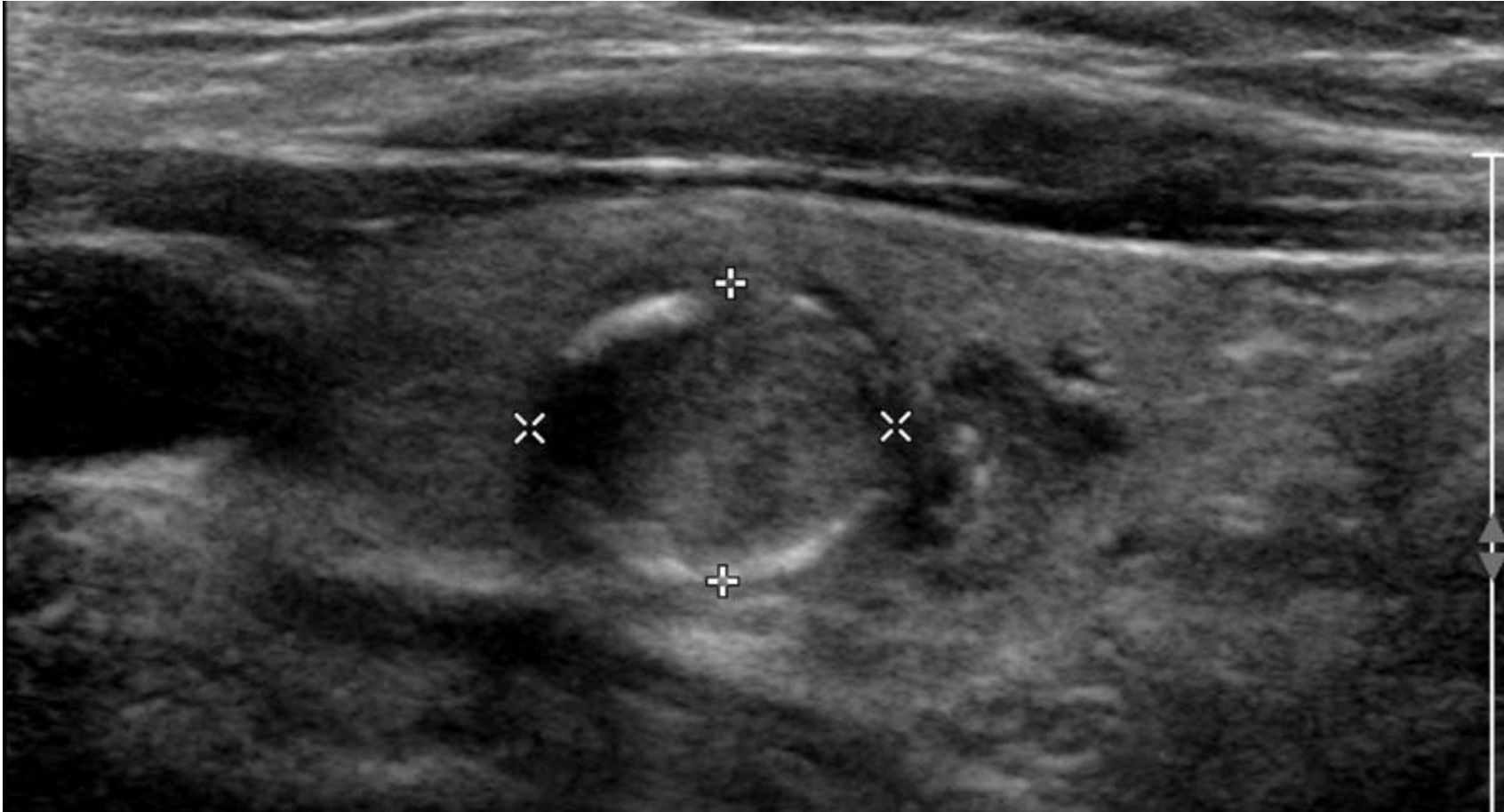
This nodule has large macrocalcifications with acoustic shadowing.

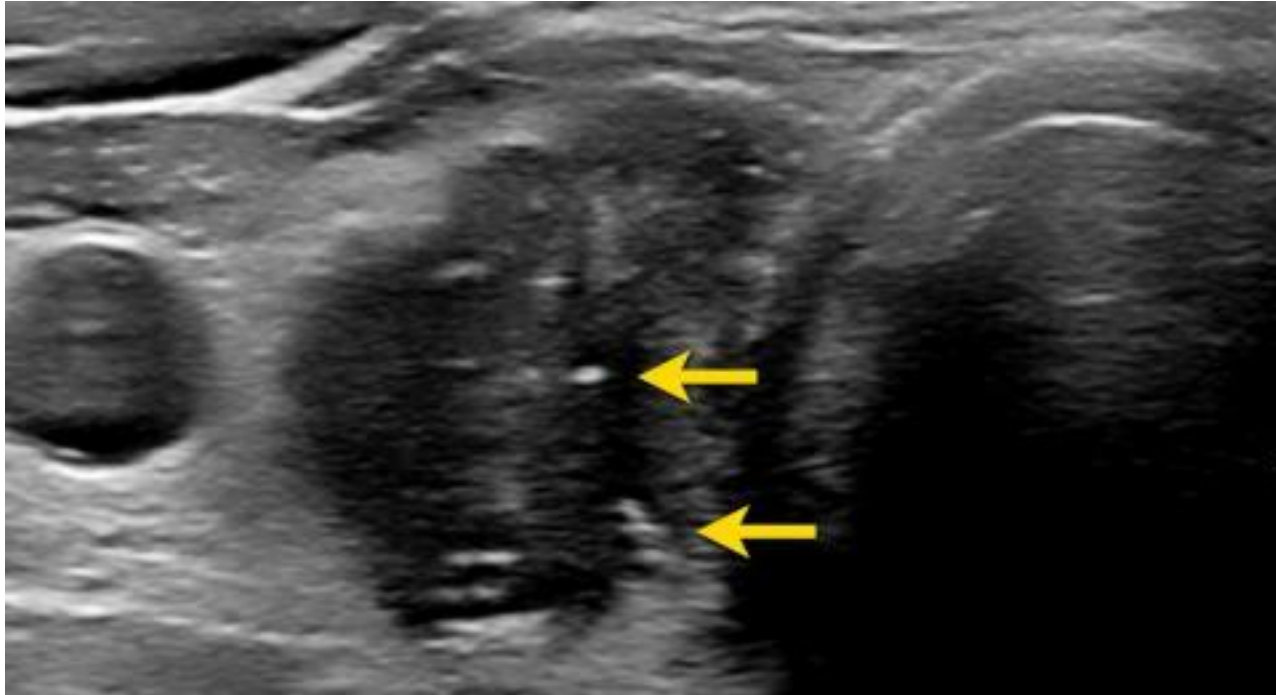
TI-RADS: 1 point.



Rim calcification

Peripheral rim calcifications can be complete or incomplete.
TI-RADS: 2 points.



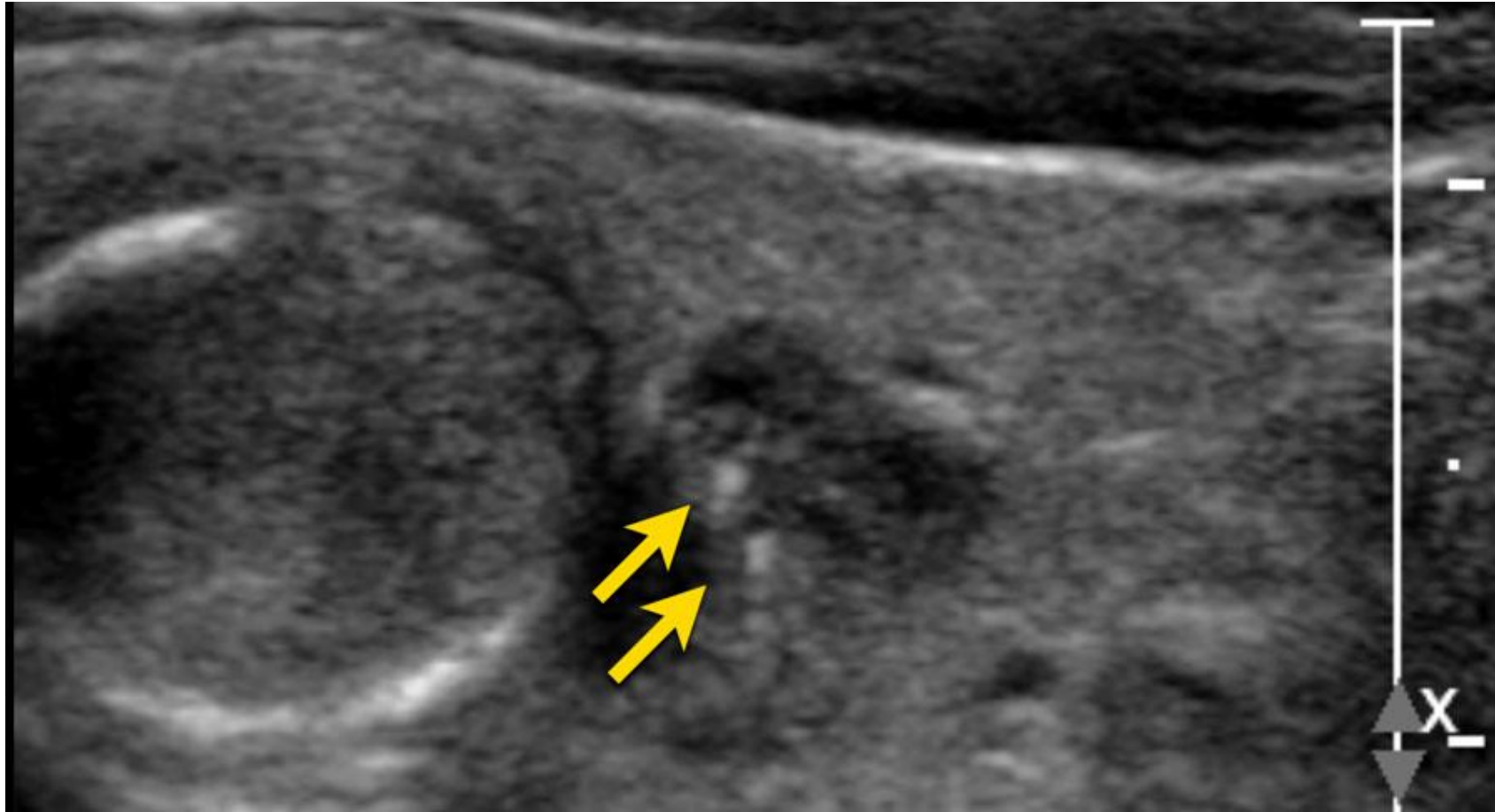


Microcalcifications

Punctate echogenic foci are also known as microcalcifications. They are a strong predictor of malignancy and therefore get 3 points.

The ACR lexicon further defined this category, because in the normal thyroid there also may be echogenic foci visible.

Punctate echogenic should be called in the situation where they are obvious and only visible within the nodule.



Small comet tail artifacts with a length less than 1mm are also included in this category.
TI-RADS: 3 points

